

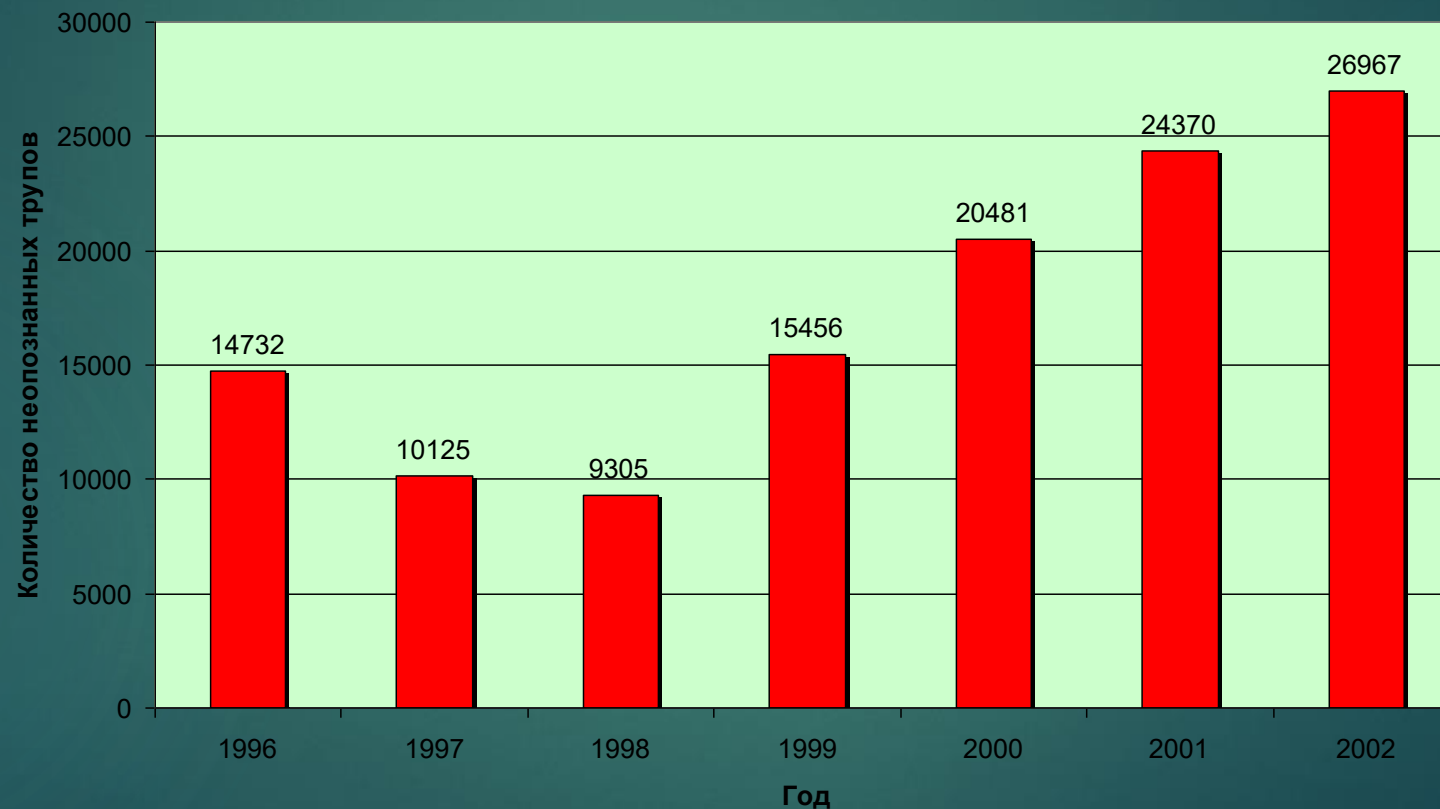


# Forensic medical identification



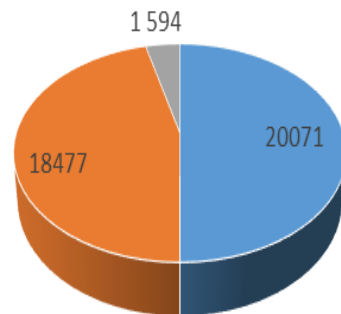
PIGOLKIN YU.I., PROFESSOR, MD,  
PHD, CORRESPONDING MEMBER OF  
RAS

# Quantity of unidentified corpses in Russia (1996-2002)



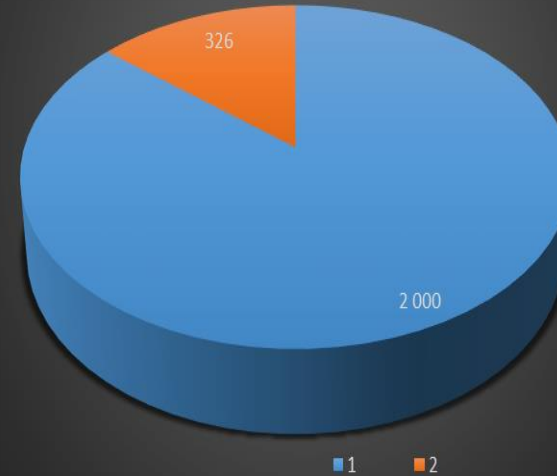
According to the Ministry of Internal Affairs of Russian Federation, 20 071 corpses were registered as unidentified at the for the period January-March 2016. During this period, only 1,594 were identified. 18 477 bodies remain unidentified as of the end of March 2016.

по данным МВД России на период январь-март 2016 года



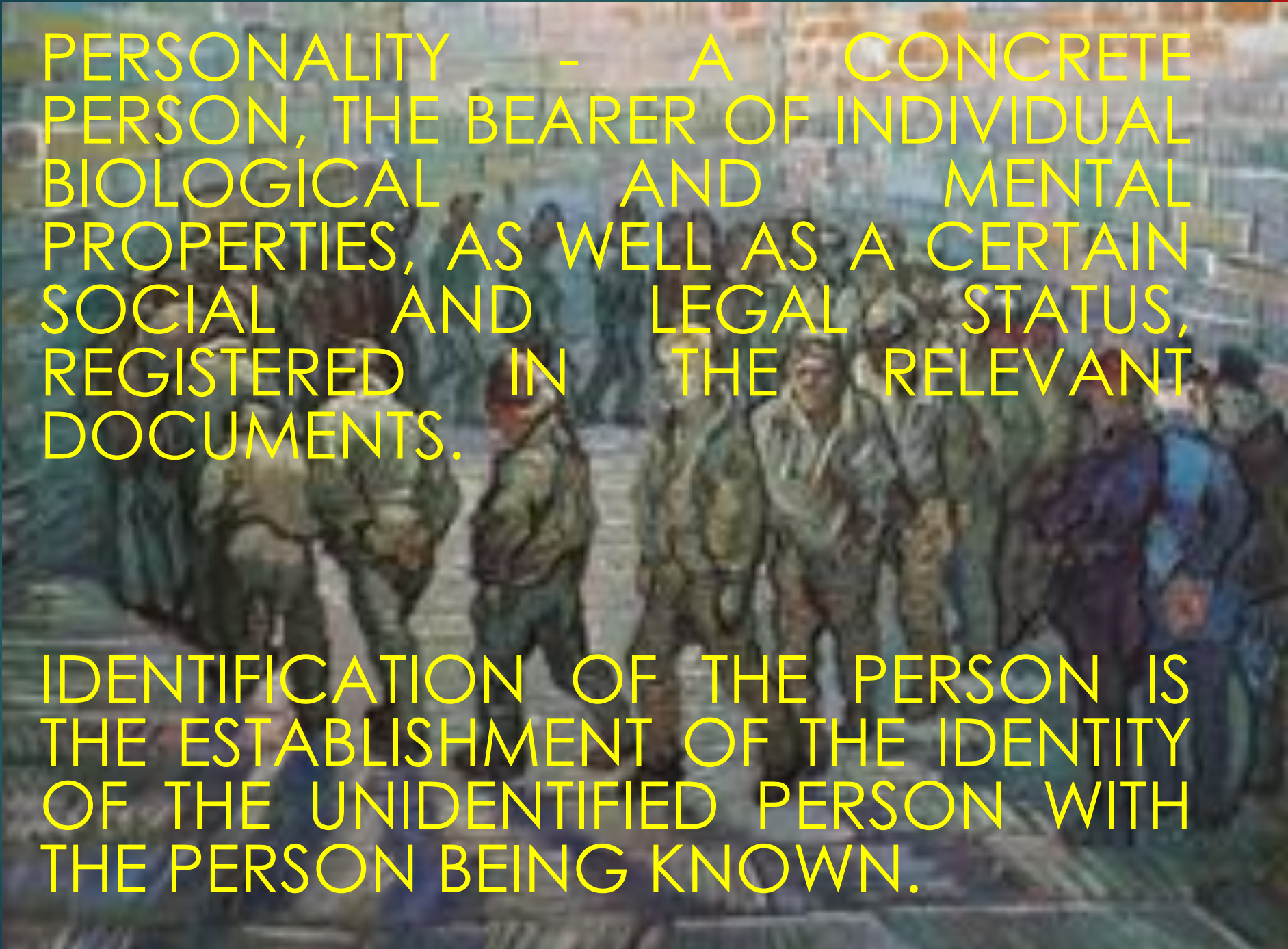
- количество дел по установлению личности неопознанных трупов
- ЧИСЛО НЕОПОЗНАННЫХ ТРУПОВ
- ЧИСЛО ОПОЗНАННЫХ ТРУПОВ

количество неопознанных трупов  
за 2015 год по г. Москве.



2 000 unidentified corpses, including "criminal", were found in Moscow in 2015. During the year, only 326 corpses were identified.



A group of soldiers in camouflage uniforms are walking through a city street. The soldiers are in the foreground and middle ground, moving from left to right. The background shows a city street with buildings and other people. The text is overlaid on the image in a bright yellow color.

PERSONALITY - A CONCRETE PERSON, THE BEARER OF INDIVIDUAL BIOLOGICAL AND MENTAL PROPERTIES, AS WELL AS A CERTAIN SOCIAL AND LEGAL STATUS, REGISTERED IN THE RELEVANT DOCUMENTS.

IDENTIFICATION OF THE PERSON IS THE ESTABLISHMENT OF THE IDENTITY OF THE UNIDENTIFIED PERSON WITH THE PERSON BEING KNOWN.

# IDENTIFICATION

- Identification is an investigative action
- Identification of the corpse is carried out by presenting a corpse of an unknown person and his clothes for the recognition to persons who could have known or seen him during his life (relatives, acquaintances, witnesses)

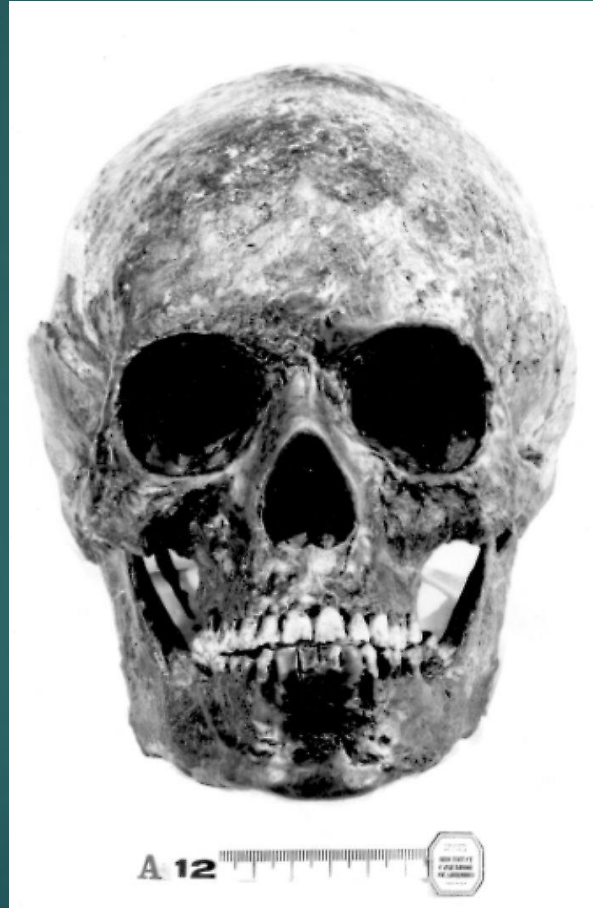

# Graphic reconstruction of the human face

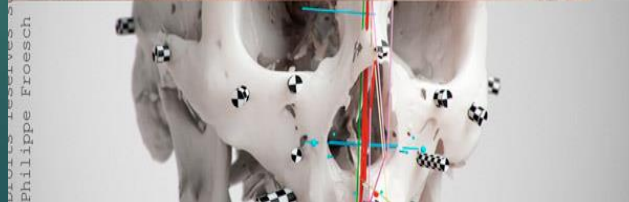
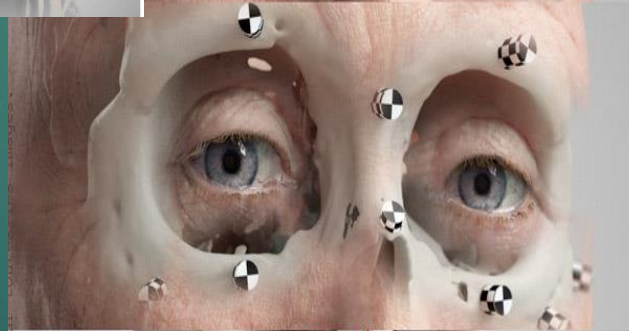
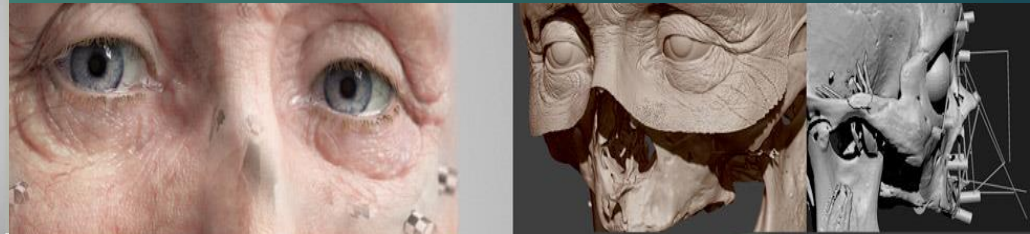
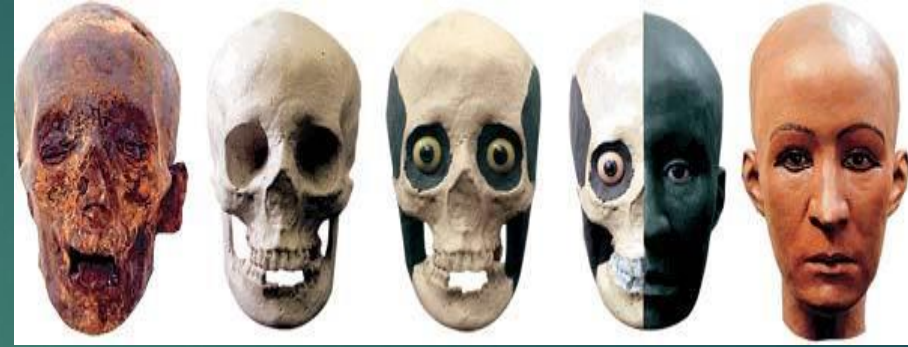
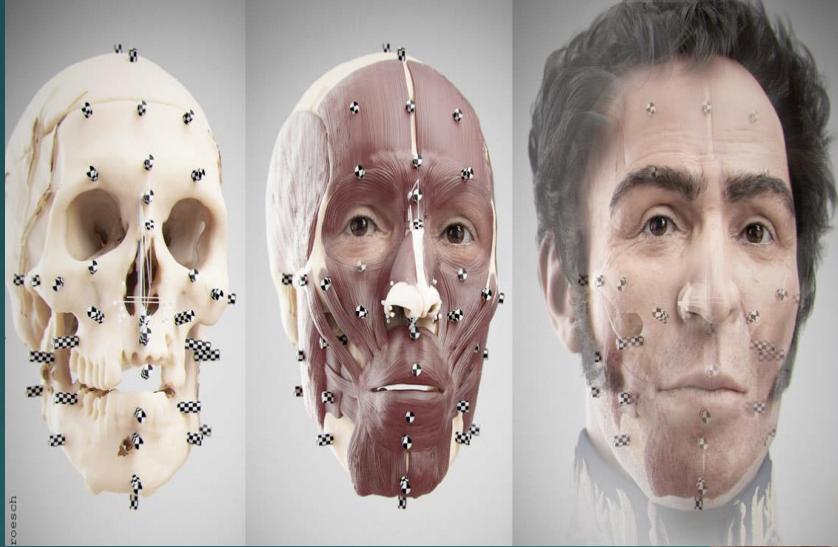
# Graphic reconstruction of the human face (V. Bering)

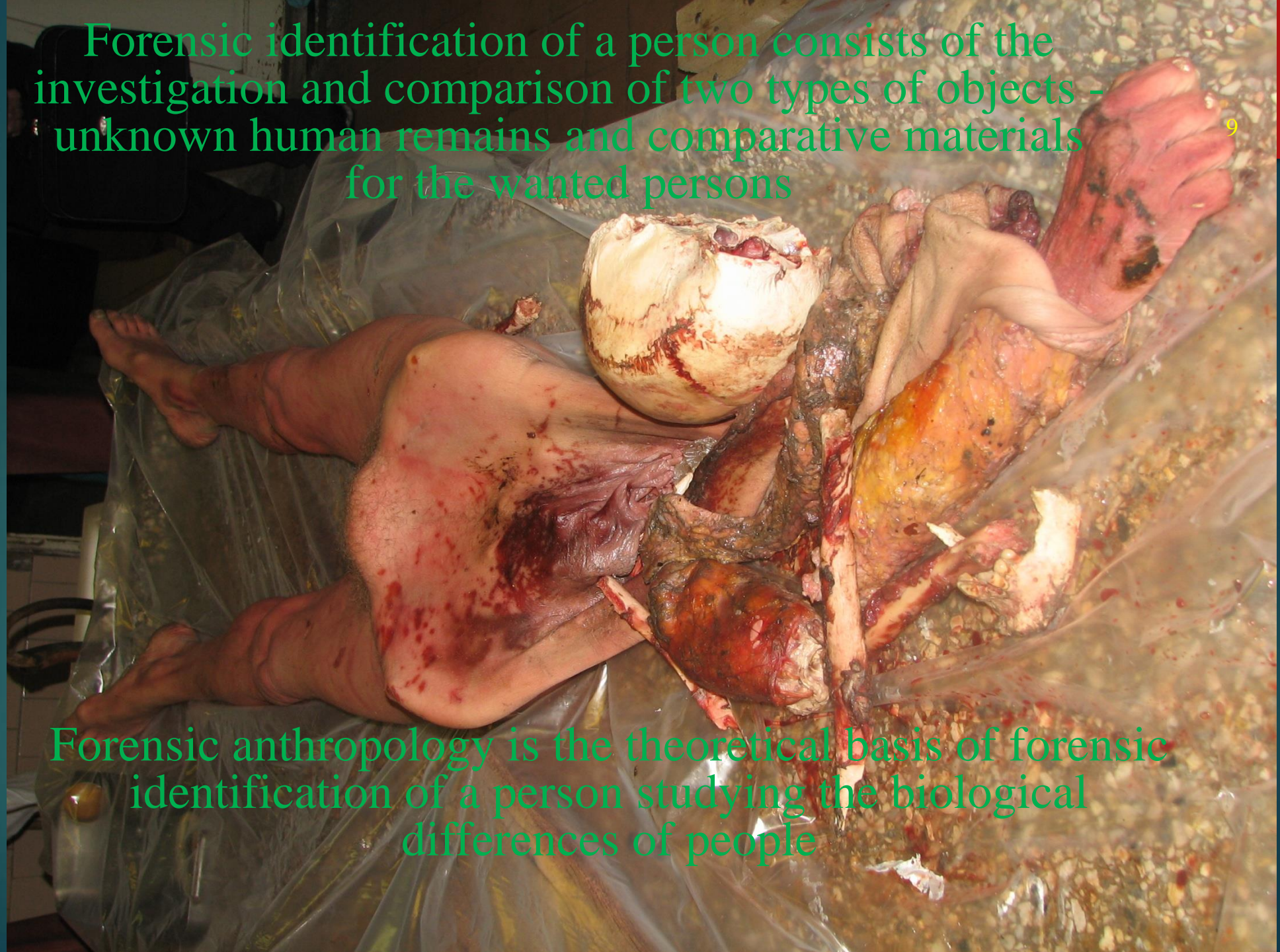

# Method of graphic reconstruction of the appearance of a person during life by the skull





Forensic identification of a person consists of the investigation and comparison of two types of objects - unknown human remains and comparative materials for the wanted persons



Forensic anthropology is the theoretical basis of forensic identification of a person studying the biological differences of people

- The possibility of identifying a person is based on the combination of individual physical characteristics (uniqueness) of each person. These include general (permanent) and particular (non-permanent) signs of personality

### General signs of personality

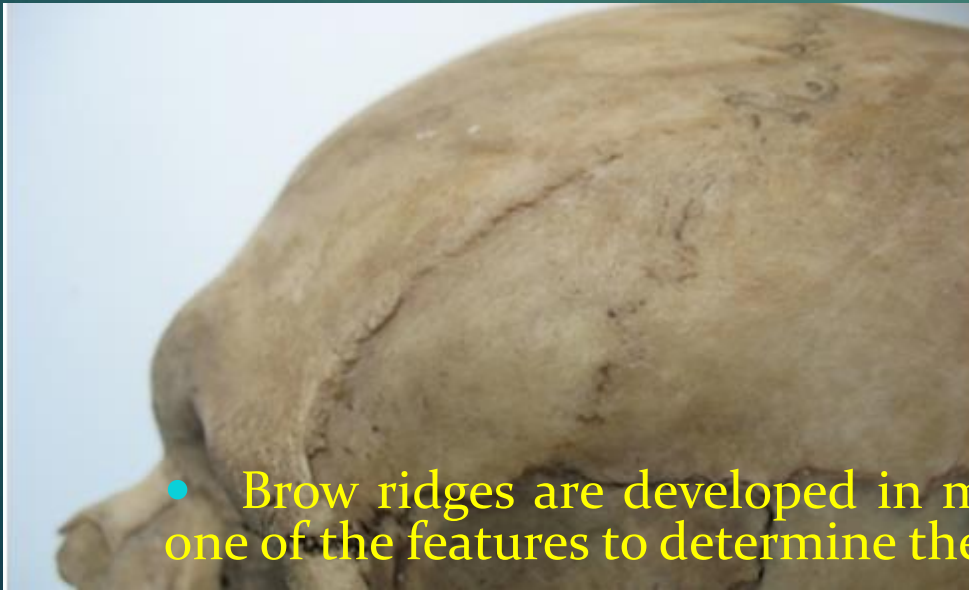
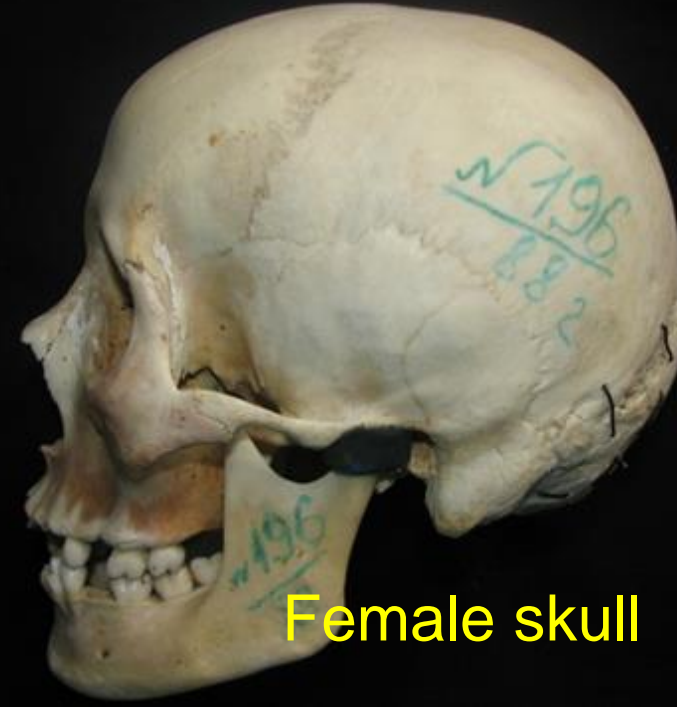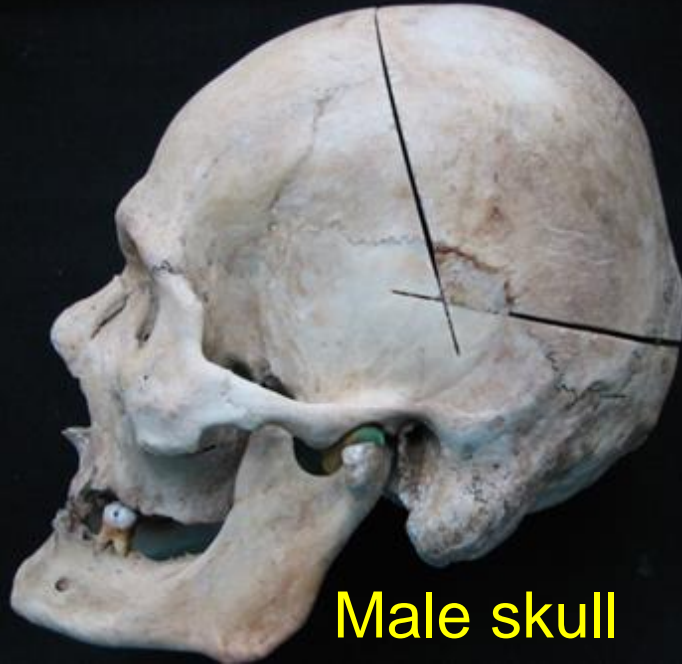- ▶ sex
- ▶ age
- ▶ growth
- ▶ race and ethnic group
- ▶ body type
- ▶ body weight
- ▶ antigenic properties

- The individualizing significance of general signs of personality lies in the impossibility of their detailed coincidence in different people.



# Sex determination

## ► Osteometric sex characteristics:



- Brow ridges are developed in men more than women, and they are one of the features to determine the sex by the skull.



# Sex determination

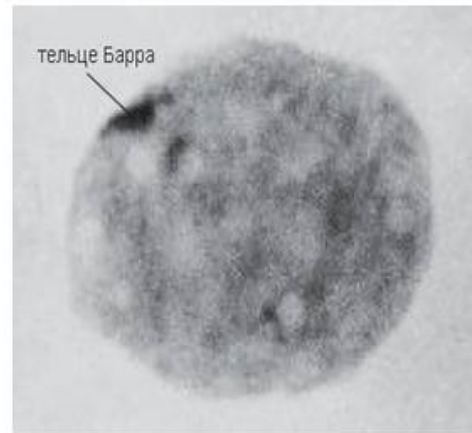
12

Macroscopic sex characteristics of the organism:

Microscopic sex characteristics of the organism:

## Половой хроматин

- **Материал – буккальный эпителий**
- **Материал распределяется по предметному стеклу и без предварительной обработки окрашивается ацетоарсеином.**
- **При микроскопии наличие в ядрах клеток одного тельца Барра означает, что клетки содержат две X – хромосомы, 2-х телец Барра – три X-хромосомы, отсутствие телец Барра означает содержание в каждой клетке одной X-хромосомы.**



- ▶ **Molecular genetic characteristics of the organism:**  
Diagnosis is based on the identification of X and Y chromosomes

# Determination of height

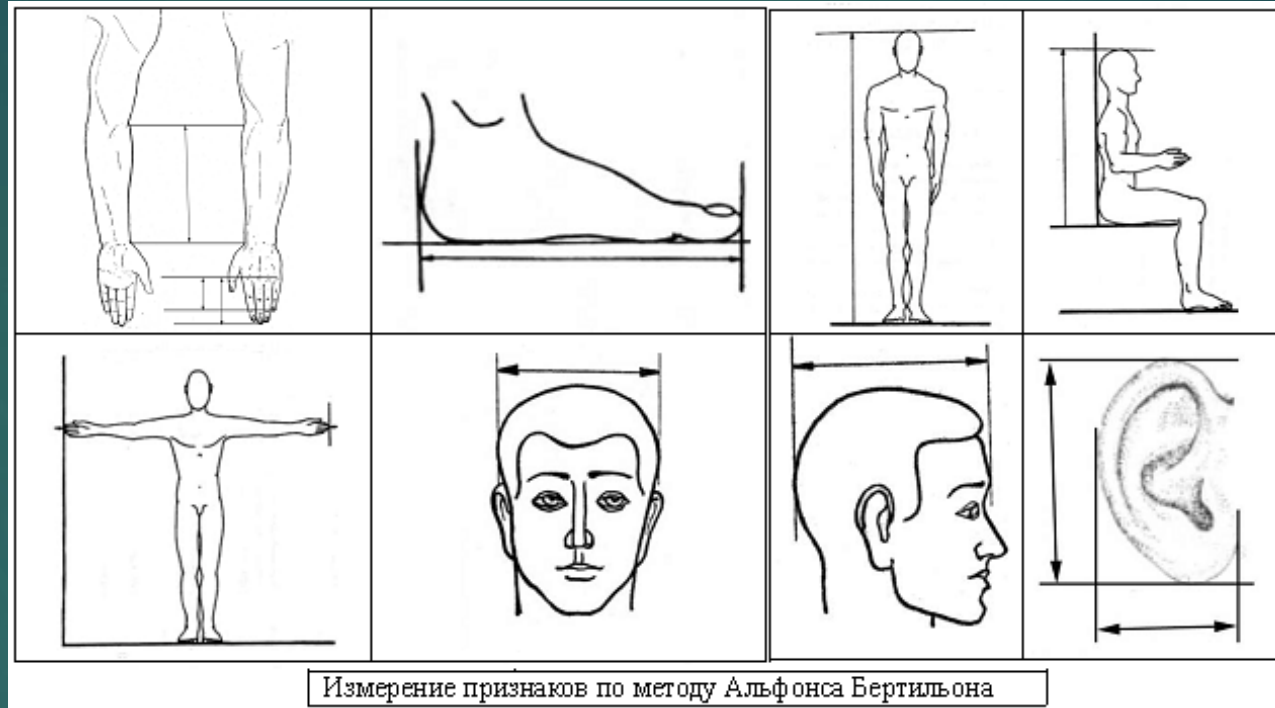
13

- The sizes of bones depend on the bodies' height. This relationships were studied by Russian scientists V.A. Betz (1887) and N.P. Gundobin (1906).

- The accuracy of determining the growth by long tubular bones is within  $\pm$  3-5 cm



# The determination of sizes of various body parts (A. Bertilion method)



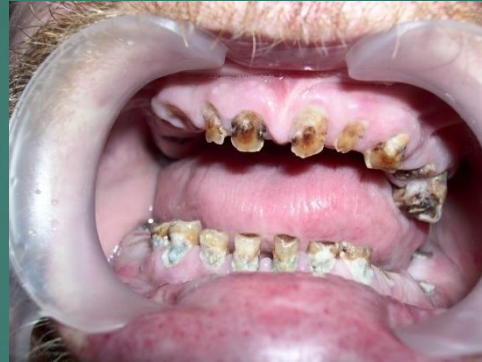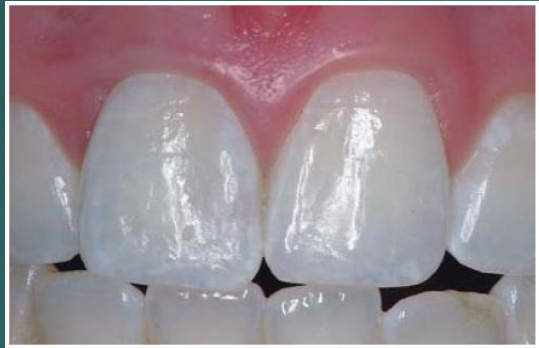This method include measuring of 11 parameters of the human body: standing and sitting height, the arms range, the length and width of the head, the length and width of the right ear, the length of the left forearm, the foot, III and V fingers of the hand



# Age determination

- ▶ Macroscopic characteristics of age
  - ▶ height
  - ▶ sex characteristics

## Dental status



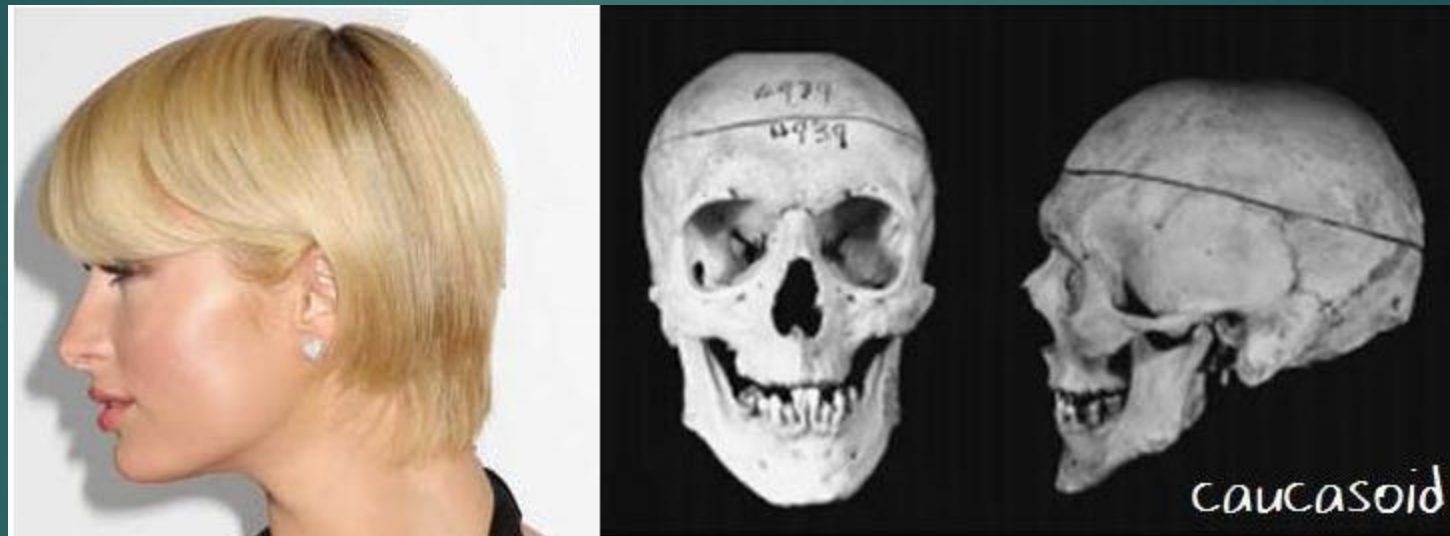Involutive changes in  
skin, bones,  
cartilages



# The determination of race and ethnical group

16

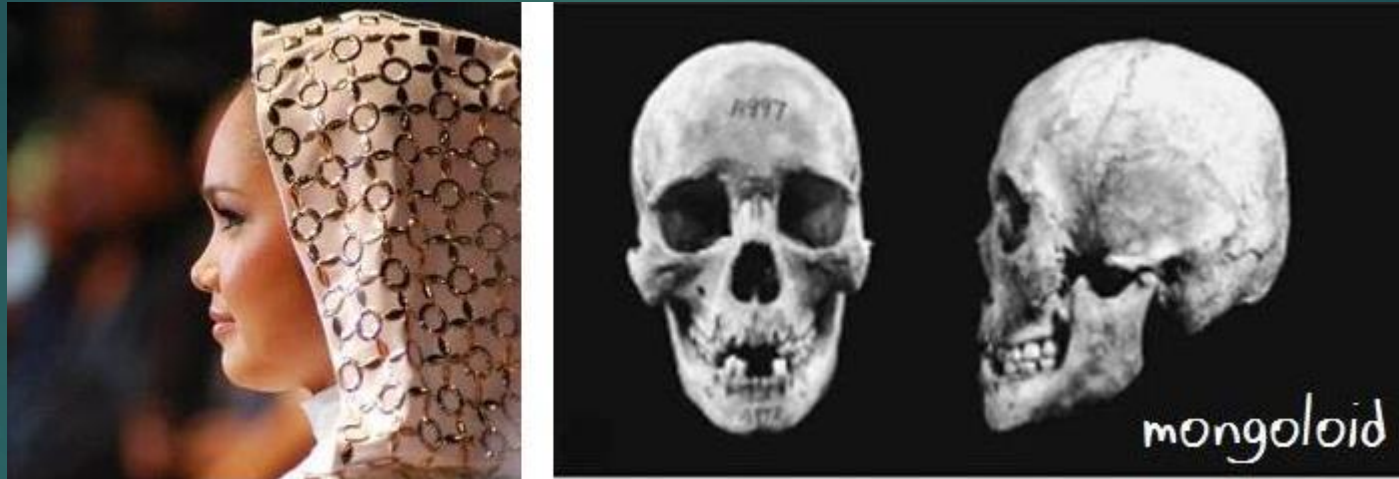- ▶ There are three main racial groups: Caucasoid, Negroid, Mongoloid. Each of them is characterized by features of the structure of the skeleton. Mostly, racial features are expressed in the structure of the skull



- In Caucasians facial skeleton stands sharply in the horizontal plane. Nasal bones are narrow. Canine fossae are expressed markedly. Wisdom teeth are not developed enough. The height of the crowns of the second and third upper molars is close to the height of the crown of the first molar

# The determination of race and ethnical group

17

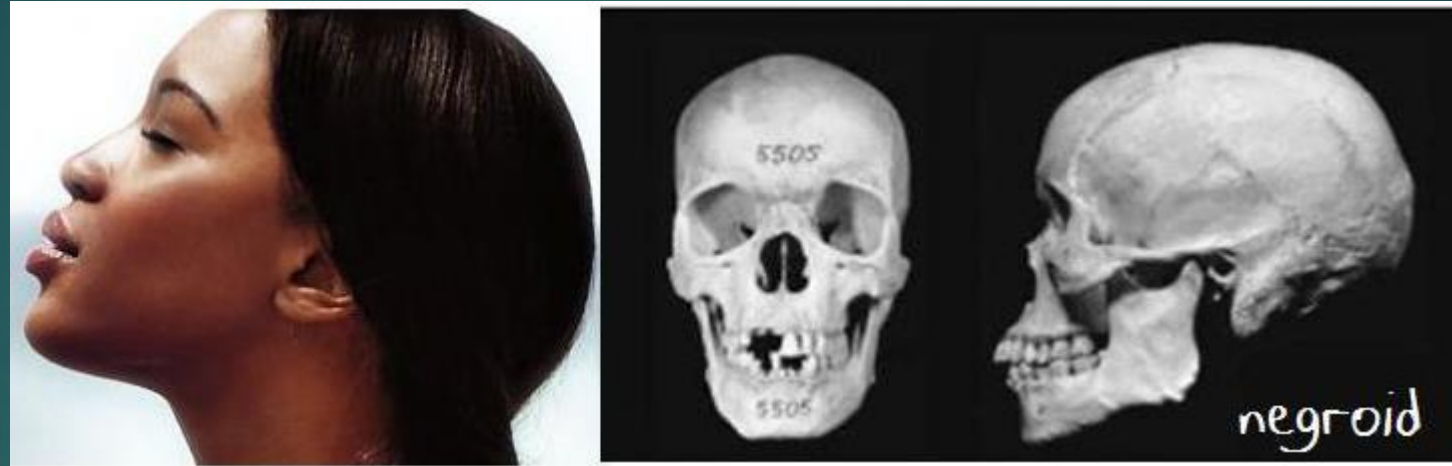

The Mongoloid has a large skull. The facial skeleton of the skull is flattened and elongated. Orbits are high. The transference is shallow. Chest bones, as a rule, are highly developed. The dog fossae are flattened. The forehead and sky are wide. The lingual surface of the upper incisors is shovel-shaped, with the presence of comb-like ridges along the vertical edges, an additional pointed "encrusted" enamel is observed in the inter-root space. On the inner surface of the alveolar processes of the upper jaw, in the projection of large molars, pronounced bony tubercles



# The determination of race and ethnical group

18




The Negroid has a wide skull, narrow forehead. The face of the skull is flattened. The cheek bones are moderately pronounced. The alveolar process of the upper jaw and the upper incisors protrude forward. Teeth are large. The second and third molars are elongated vertically.

There are numerous variants between the main racial groups. They are diagnosed using craniometric indicators, the reliability of which is provided by the use of one-dimensional and canonical discriminant analysis

## Definition of body type

19



*Ectomorphic Mesomorphic Endomorphic*

Is determined by the comparison of the quantitative characteristics of the bones of the upper limbs, spine, thorax, pelvis and lower limbs

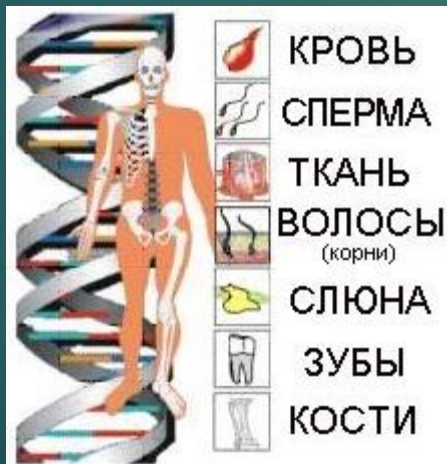## Determination of antigenic properties of tissues

- ▶ By the traces of blood, sperm and other secretions, hair, particles of organs and tissues.
- ▶ Proving of the biological essence of the trace (blood, sperm, etc.),
- ▶ Species origin (belonging to man or animal)
- ▶ Possibility of determination of particular person



# Molecular genetic method (A. Jefferison, 1984)

The following principles are the basis of molecular genetic identification:



Объекты STR-локусы	Объект № 13 Образец крови К...	Объект № 14 Образец крови Л...	Объект № 15 Образец крови М...
Amelogenin	пол известен	пол известен	пол известен
D3S1358	14,15	18,18	16,17
D5S8818	10,11	10,12	10,11
D8S1179	11,15	12,12	12,12
TPOX	10,11	8,11	8,9
D16S539	9,11	11,11	10,11
CSF1PO	11,11	10,12	10,11
TH01	6,9,3	6,6	7,9
D13S317	12,12	9,11	10,11
D7S820	10,10	10,11	11,11
D18S51	12,12	16,18	16,18
D2S1338	19,20	17,20	17,17

## Molecular-genetic age characteristics of the organism

- ▶ The method is based on the analysis of T cells. T cells constantly update new receptors on their surface. At the same time, they "cut off" fragments of DNA and make new sequences from them. "Wastes" of this process are circular DNA fragments that do not have any function
- ▶ As a result of the analysis of such structures, it is established that number of the receptors decreases with the age, because the organism produces less and less T-cells
- ▶ This method allows you to determine the age of a person with an error of 10 years and does not require comparison. A definition of the approximate age may significantly narrow the range of suspects

## Definition of particular personality signs

- ▶ Private signs of personality reflect the anatomical features of the organism of a particular person
- ▶ They are divided into:
  - ▶ congenital signs of personality
  - ▶ acquired signs of personality: traces of injuries, surgeries, tattoos, etc.




## **Congenital signs of personality are the individual features and anomalies of the development of the organism:**

- ▶ construction of individual elements of the bone system (frontal and maxillary sinuses, beams and cellular bone structures, etc.)
- ▶ Age-related changes in the skeleton (osteophytes, local osteoporosis, sclerotic changes, etc.)
- ▶ papillary patterns of fingers, palms, feet
- ▶ birthmarks
- ▶ hair
- ▶ irises
- ▶ skin

# Congenital signs:

The method of verbal portrait is the description of appearance using special conditional standard terms



# Congenital signs:

Photographic method:

The photo of the person being searched is compared with the skull photo

26

**Традиционный способ фотосовмещения**

1. Репродукция фотоснимка, получение негатива и диапозитива.  
2. Разметка диапозитива.

3. Фотосовмещение на матовом стекле фотокамеры

4. Получение негатива черепа.  
5. Совмещение двух негативов.

6. Фотопечать совмещенного изображения

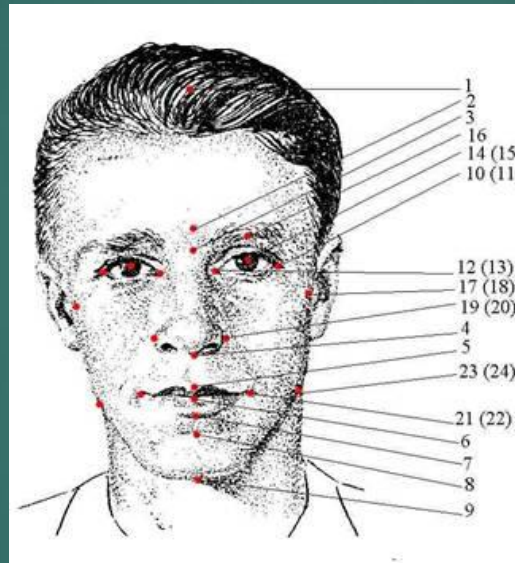
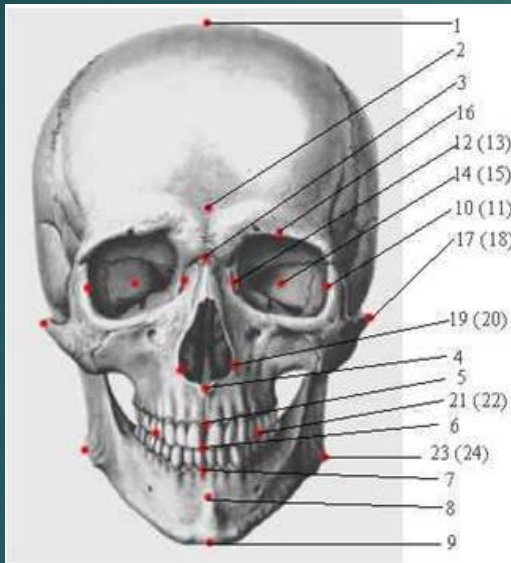
The diagram illustrates a six-step process for traditional photo superimposition. Step 1 shows a camera and a photo of a person's face. Step 2 shows a negative and a slide. Step 3 shows a camera with a slide and a skull. Step 4 shows a skull negative and a person's face negative. Step 5 shows the two negatives combined. Step 6 shows the final superimposed image. Below the diagram are three photographs: a portrait of a young man, a skull, and the skull superimposed on the man's face.

Evidence is only negative



# Congenital signs:

## ► Method of quantitative "verbal portrait"



Paradox 7 Runtime for Windows - [Report : VERBAL4]

Метод количественного словесного портрета

Российский центр судебно-медицинской экспертизы  
Отдел идентификации личности

№: 10    ФИО: Неизвестный Романов ОЗ  
Пол: м    Возраст: 45    Примечание:

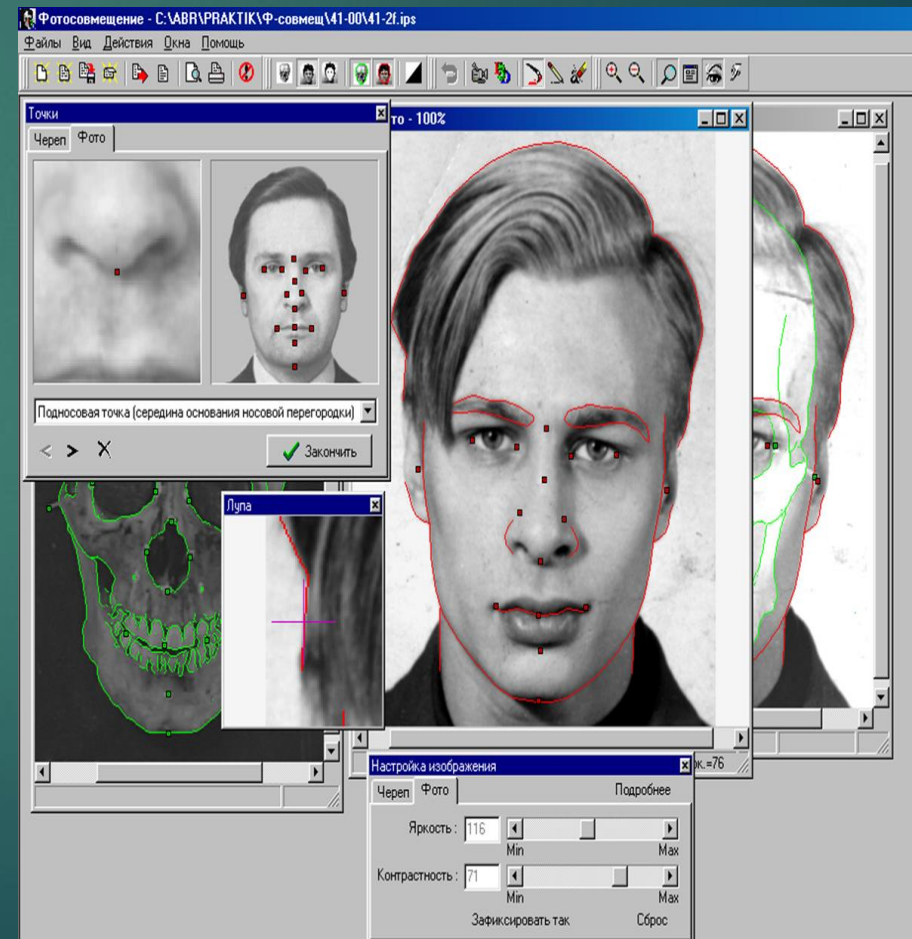
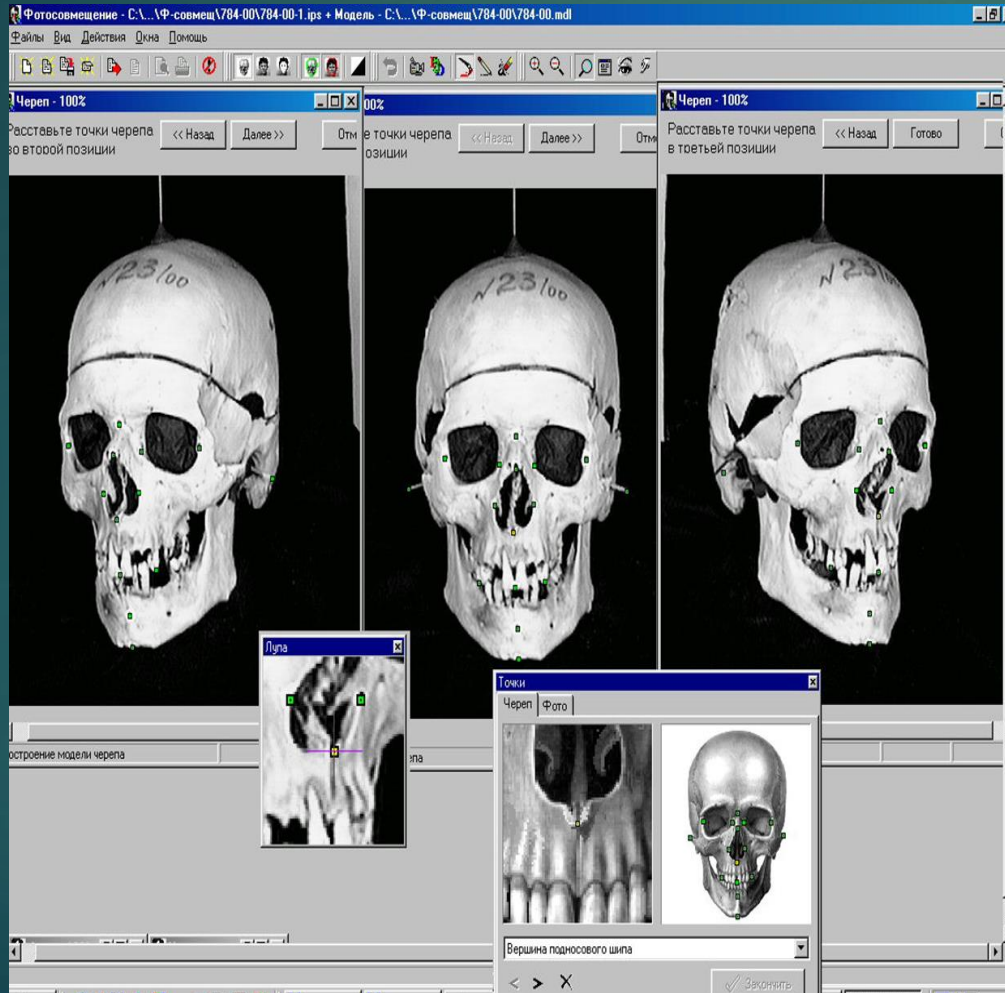
Признак	Наименование	Категории размеров		Разность
		фото	череп	
DY1	Высота лба [Y1-Y3]	2,00	2,00	0,00
DY2	Высота носа [Y3-Y4]	3,00	2,00	1,00
DY3	Высота ротоподбородочной части [Y4-Y9]	2,00	2,00	0,00
DY4	Высота брови [Y16-Y14]	1,00	1,00	0,00
DY5	Высота верхней губы [Y4-Y6]	2,00	2,00	0,00
DY6	Высота нижней губы [Y6-Y3]	2,00	2,00	0,00
DY7	Высота подбородочного бугра [Y8-Y9]	1,00	1,00	0,00
DY8	Полная высота лица [Y1-Y9]	2,00	1,00	1,00
DY9	Верхняя высота лица [Y3-Y6]	2,00	2,00	0,00
DY10	Высота красной каймы [Y5-Y7]	3,00	2,00	1,00
DY11	Высота носового отростка лобной кости [Y2-Y3]	1,00	1,00	0,00
DX1	Расстояние между наружными углами глаз [X10-X11]	3,00	3,00	0,00
DX2	Расстояние между внутренними углами глаз [X12-X13]	3,00	4,00	1,00
DX3	Ширина носа в краях [X19-X20]	2,00	3,00	1,00

Page 1 of 1

The layout of objects and the protocol of comparative research

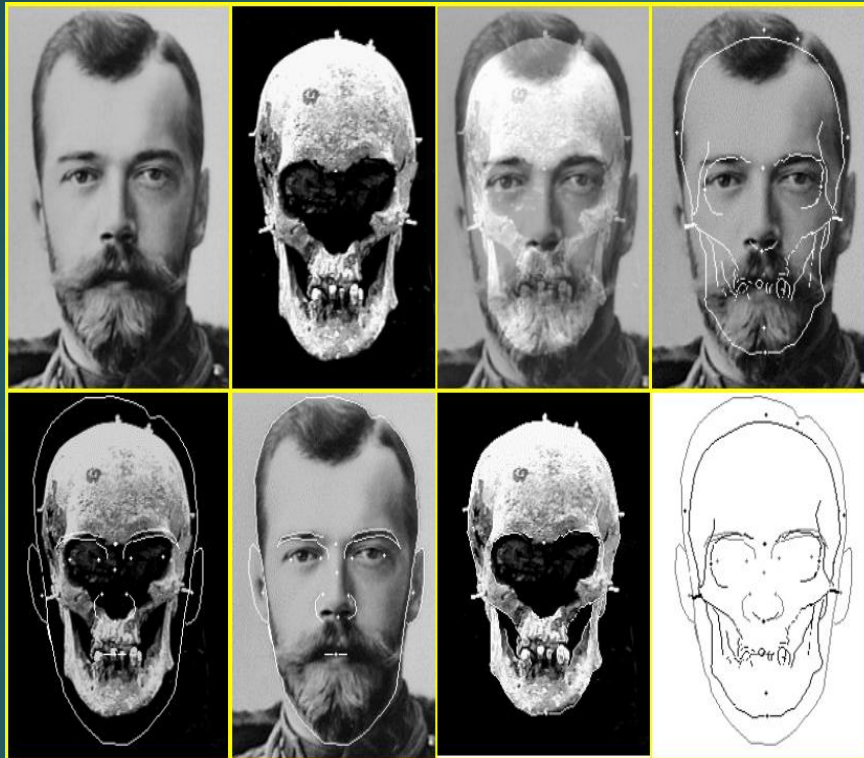
# Congenital signs:

Complete three-dimensional models of skulls allow to conduct studies using a virtual model, to keep skull information for subsequent studies

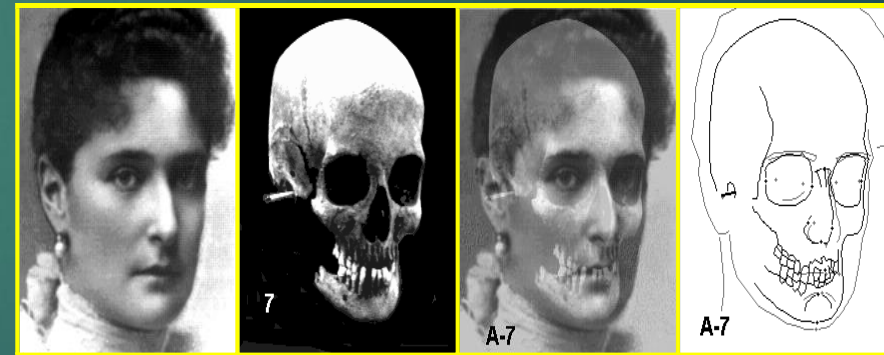


## Congenital signs:

With the help of computer technology, all skulls from the burial of the royal family were analyzed. Skulls that would have belonged to Nicholas II and Alexandra Feodorovna were identified



Компьютерное фотосовмещение одного из снимков Н.А. Романова с изображением черепа от скелета № 4. Исследованы проекционные соотношения 17 пар признаков. Результат положительный.

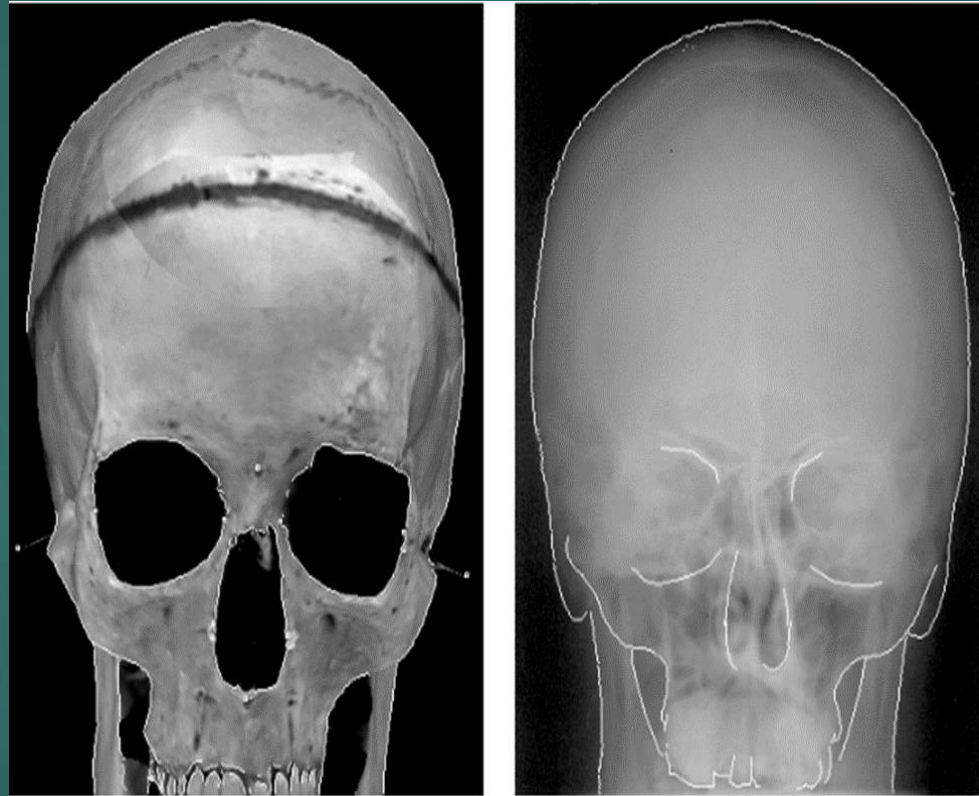

Компьютерное фотосовмещение одного из снимков  
А.Ф. Романовой с изображением черепа № 7.  
Результат положительный.



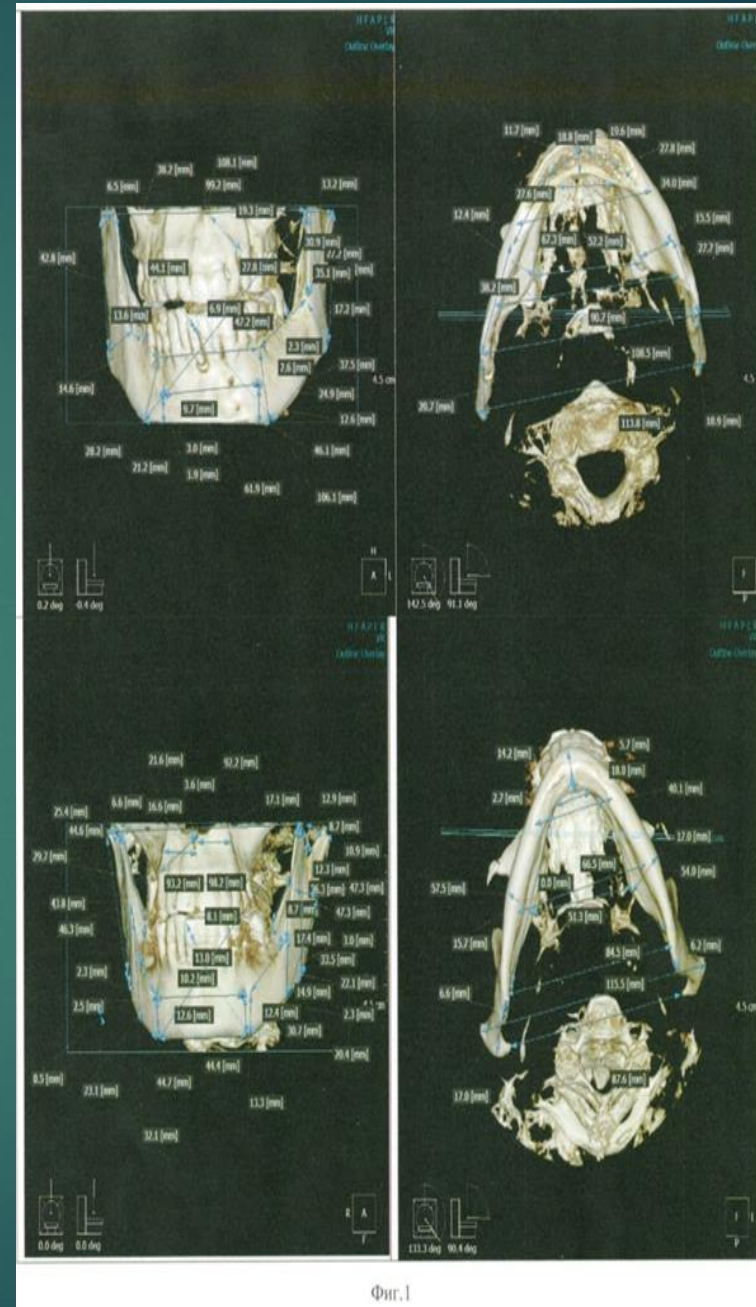
## Congenital signs:

Identification by the comparison of the skull with the intravital radiograph of the person

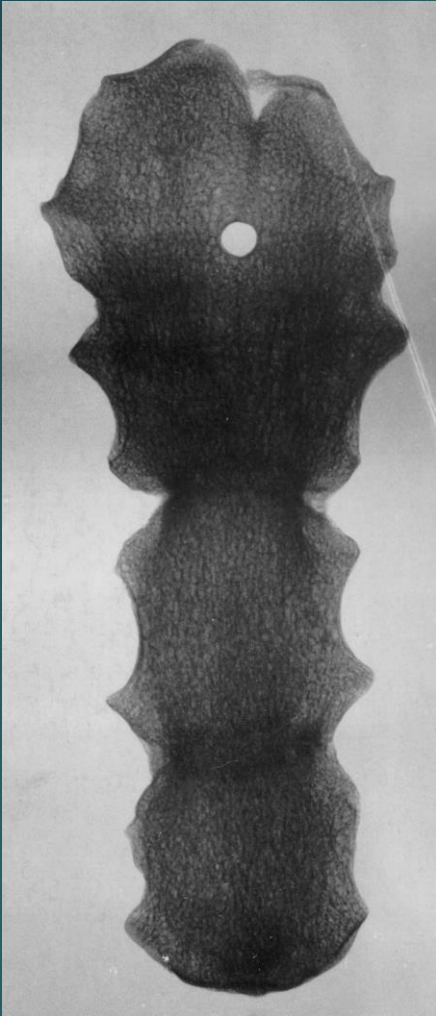


The imposition of skull contours on the contours of the radiograph of the skull - the complete coincidence of the contours of the compared objects along the arch and upper jaw

A method for identifying a person's identity from a bone fragment of the skull by the comparative X-ray study of vital and postmortem material



## Congenital signs:



**Individual elements of the bone system are distinguished by individual structural features (individual configuration of the frontal and maxillary sinuses, features of the structure and interposition of girder and cellular bone structures, etc.)**

**Congenital defect of the sternum with a ring of sclerosis of bone tissue**

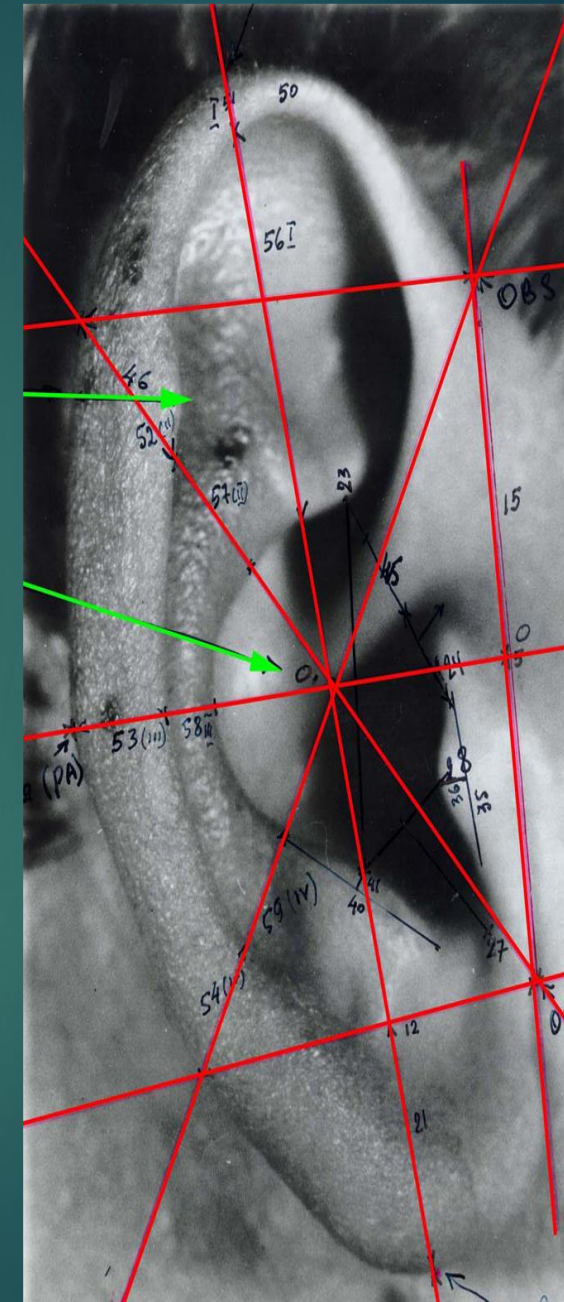
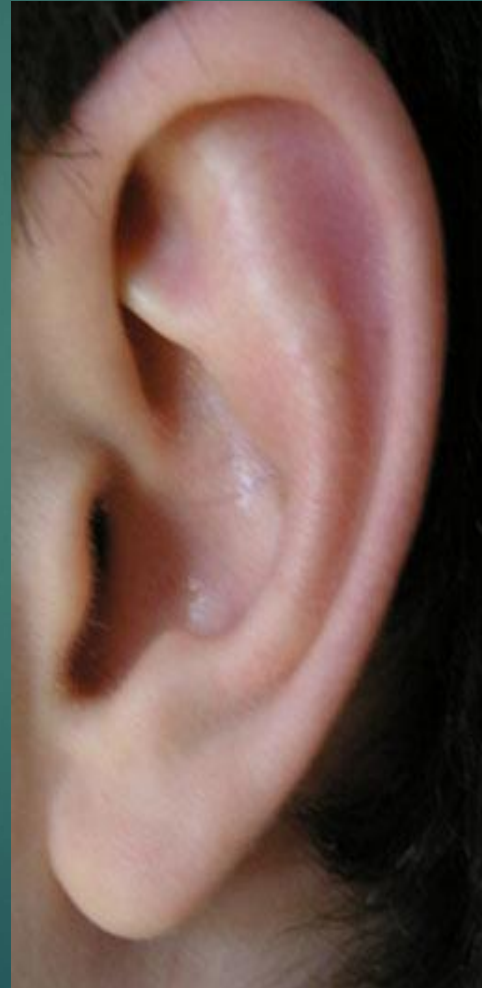

## Congenital signs:

### Identification of the person by auricle

Method of biometric identification:

We obtain identification signs by the selection of contour lines; The shape of person's ears does not change with age;



## Congenital signs:

Dactyloscopy - the study of fingerprints. This most simple and reliable method of identifying a person is based on the individuality of the skin pattern of the fingers, palms and soles, formed by ridges and furrows. These patterns appear on the 13th week of fetal development and remain unchanged throughout the life of a person.

34

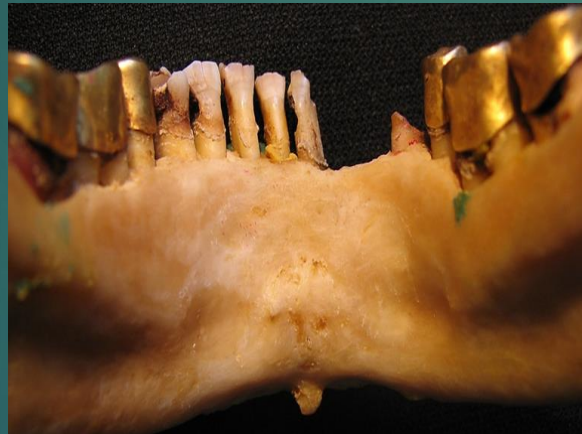
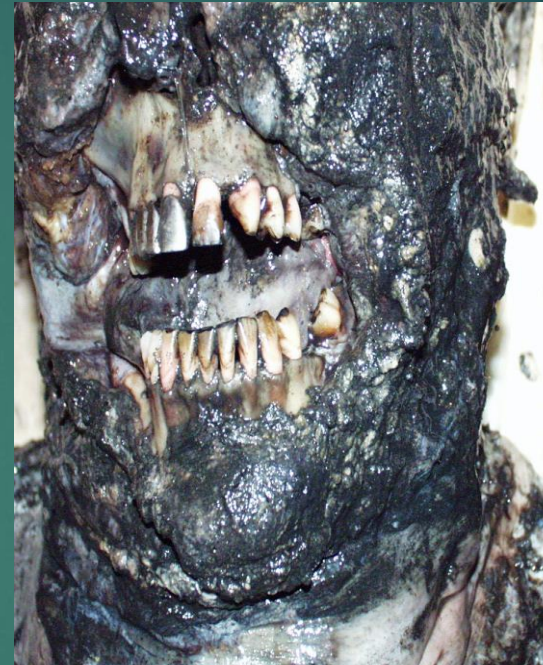
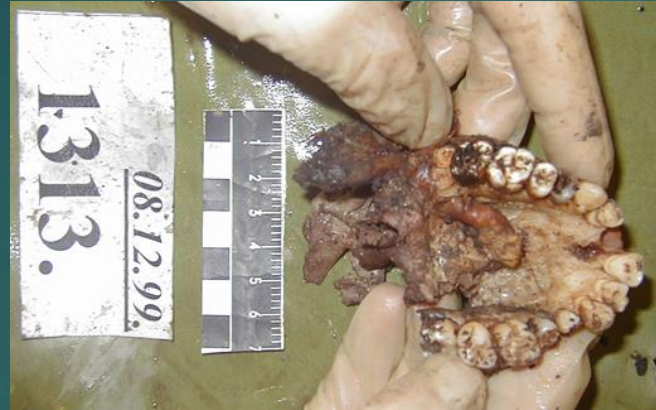


# Acquired signs

## Forensic stomatological study

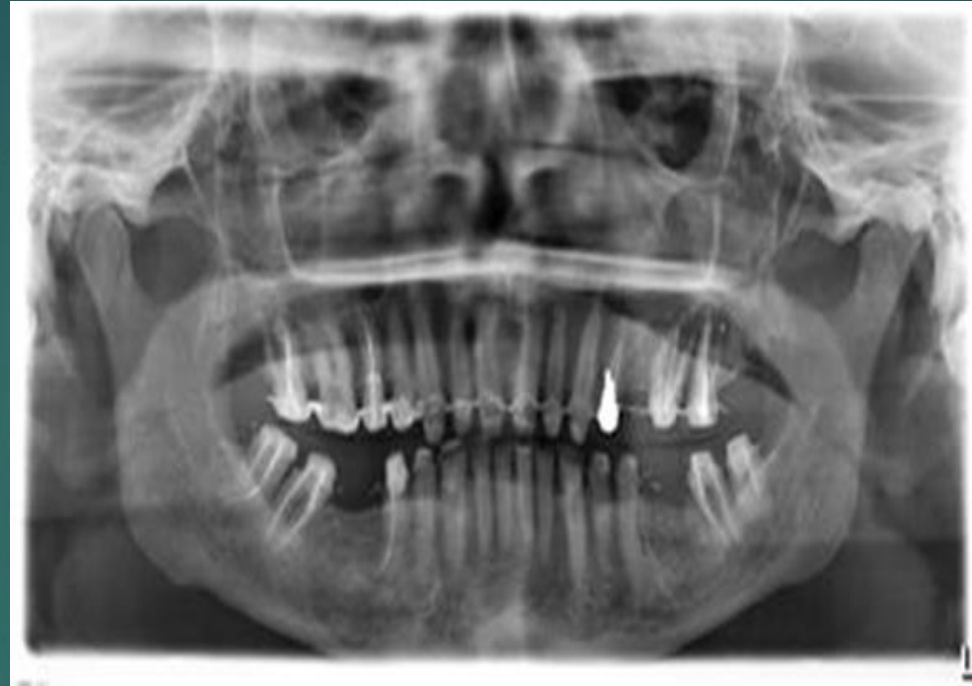35



Unique characteristics of teeth, the presence of dental diseases or the signs of treatment are used for the personal identification.



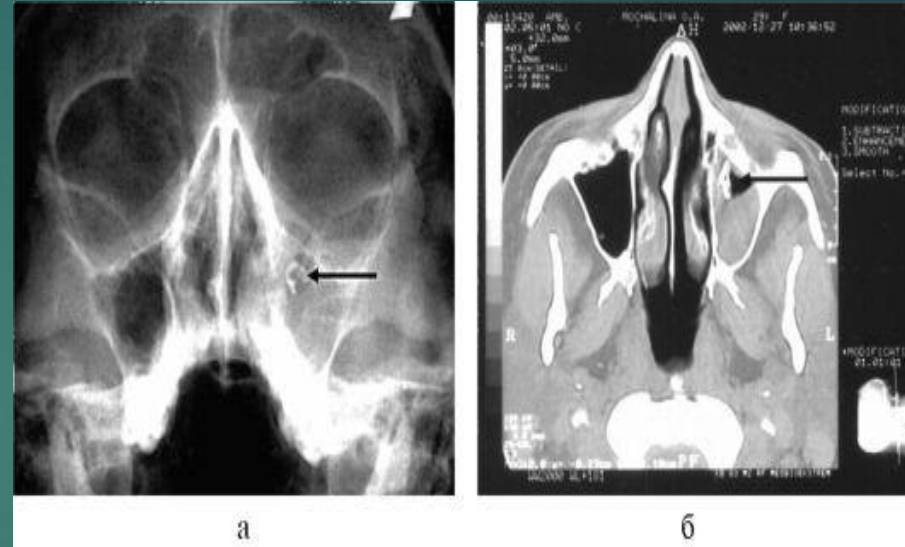
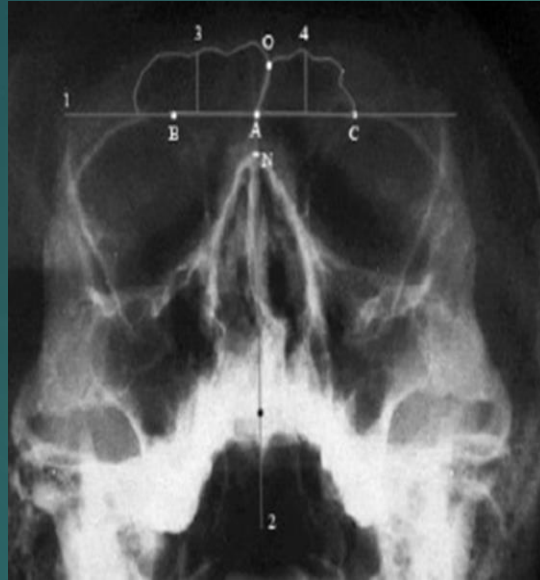
## Acquired signs



- ▶ X-ray method of identification using orthopantomography of the jaws is a comparative study by phototaping of the intravital image of the bones of the skull; it is based on the existing correlation between the corresponding elements of the structure

## Combination of congenital and acquired traits

Imposition of skull contours on the contours of the radiograph of the skull

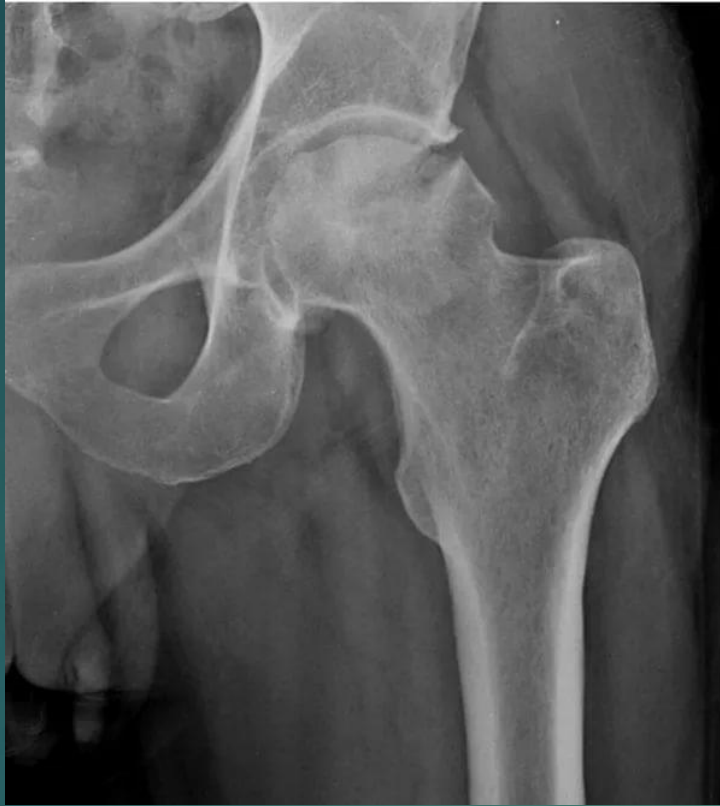

- Identification of the person according to the individual features of the configuration of the frontal sinuses on intravital and postmortem X-rays

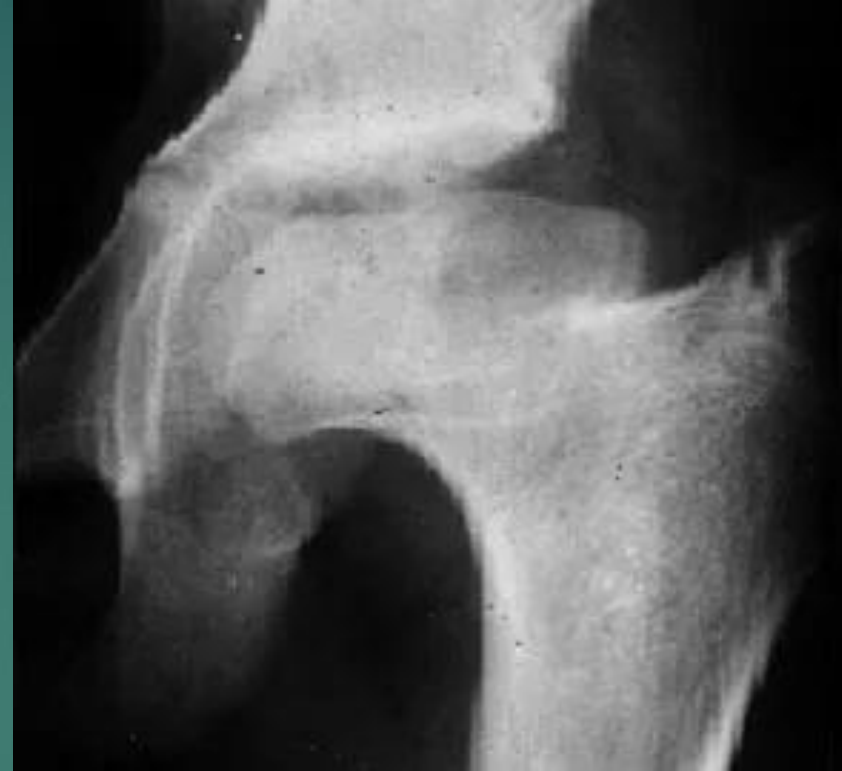On a direct radiograph of the skull (a) and CT (b) of the patient with left-sided chronic sinusitis; In the projection of the sine there is a shadow of the foreign body

## Acquired signs

38



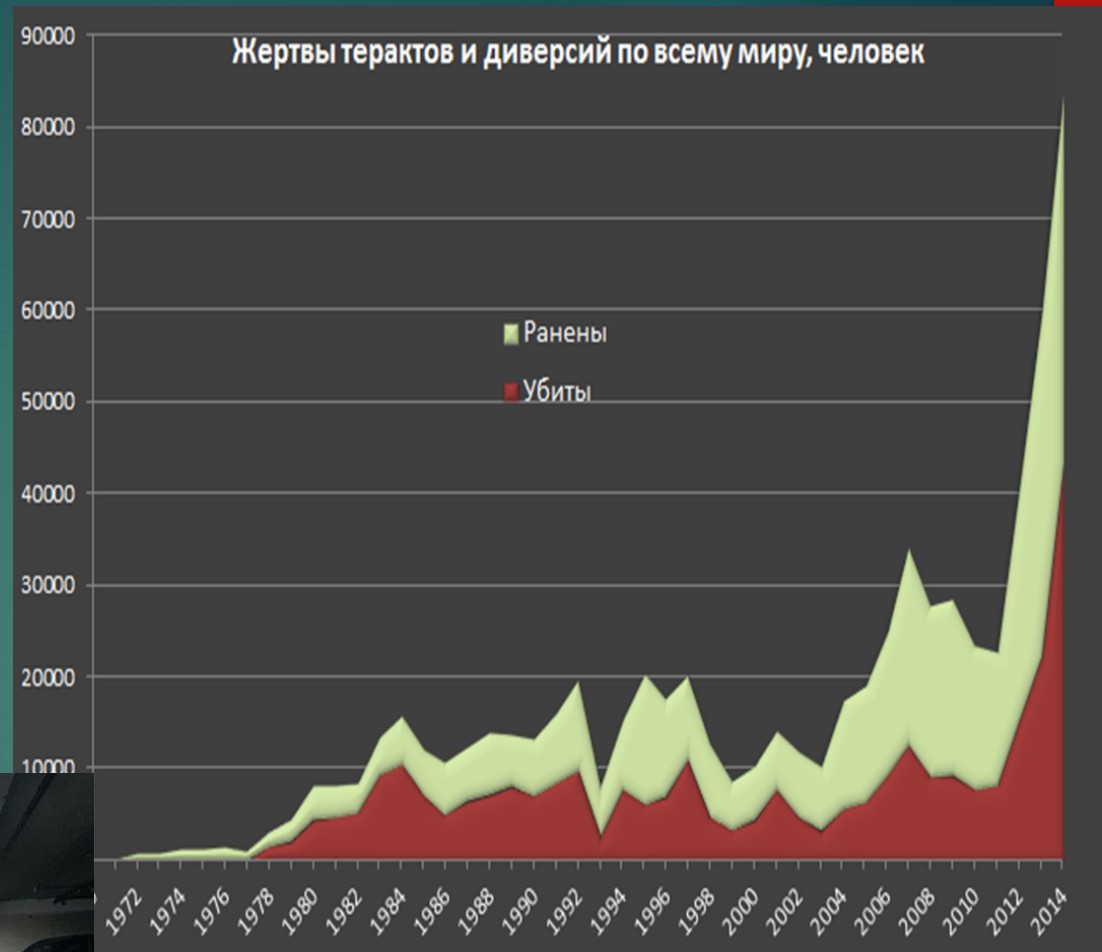
**Necrosis of the head of the femur**



**Deformation of the femoral head**



Nowadays, the number of man-made disasters and cases of terrorism has increased











# ТЕРРОРИСТИЧЕСКИЕ АКТЫ

СОВЕРШЕННЫЕ ТЕРРОРИСТАМИ-СМЕРТНИКАМИ НА ТЕРРИТОРИИ РФ  
С 2000 ГОДА

Совершено	С участием	В том числе	В результате	Более
81	123	52	1216	3263
террористический акт	смертников	женщин-смертниц	человек погибло	получили ранения

Терроризм.ру  
НЕИ



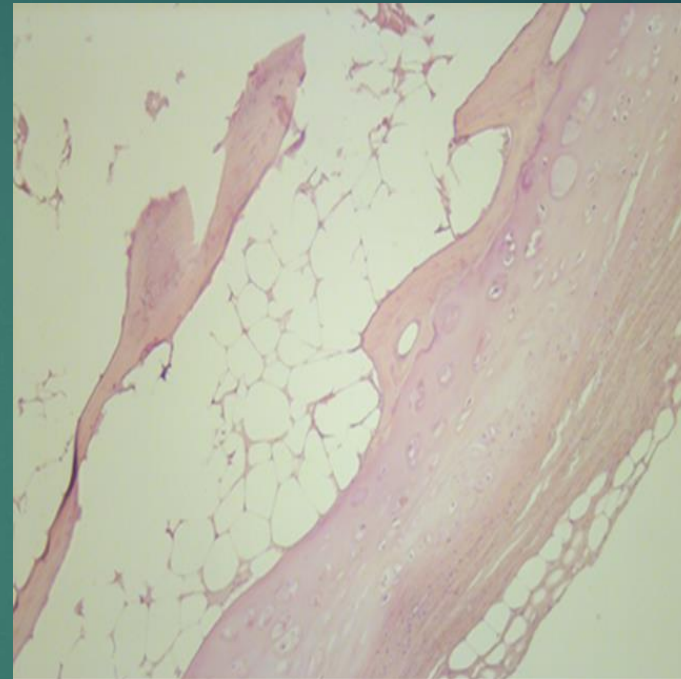
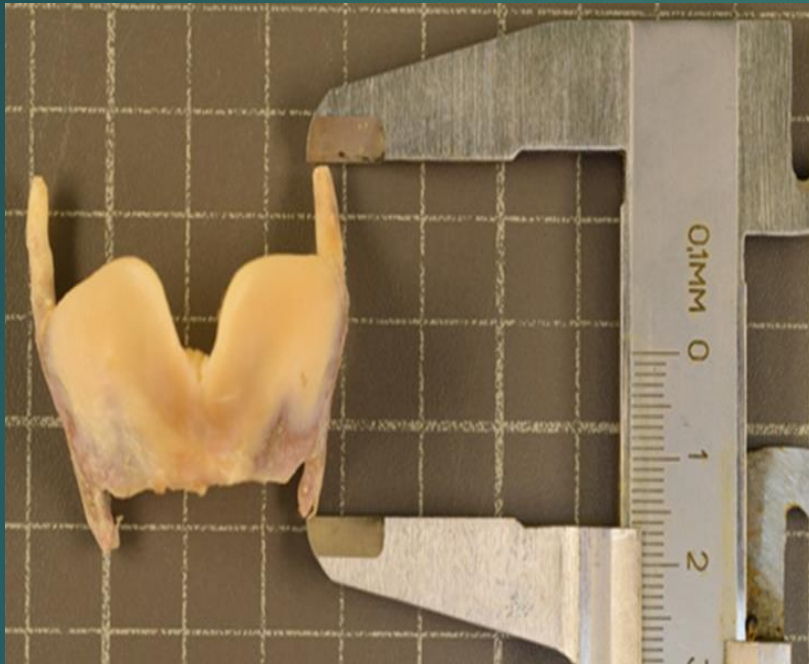


- It is important to sort the parts of the destroyed corpses by common signs: gender, age, race, height, etc.
- The most important feature is AGE.

**To solve the problems of personal identification we carried out innovative studies of age-related changes in:**

- Choline and adrenergic innervation, afferent, efferent innervation, and granulocytes of the cerebral vessels
- Capillaries of the brain
- Morphology of the thyroid cartilage
- Bone microstructure
- Radiographs of the bones of the hand
- Morphology of the Turkish saddle

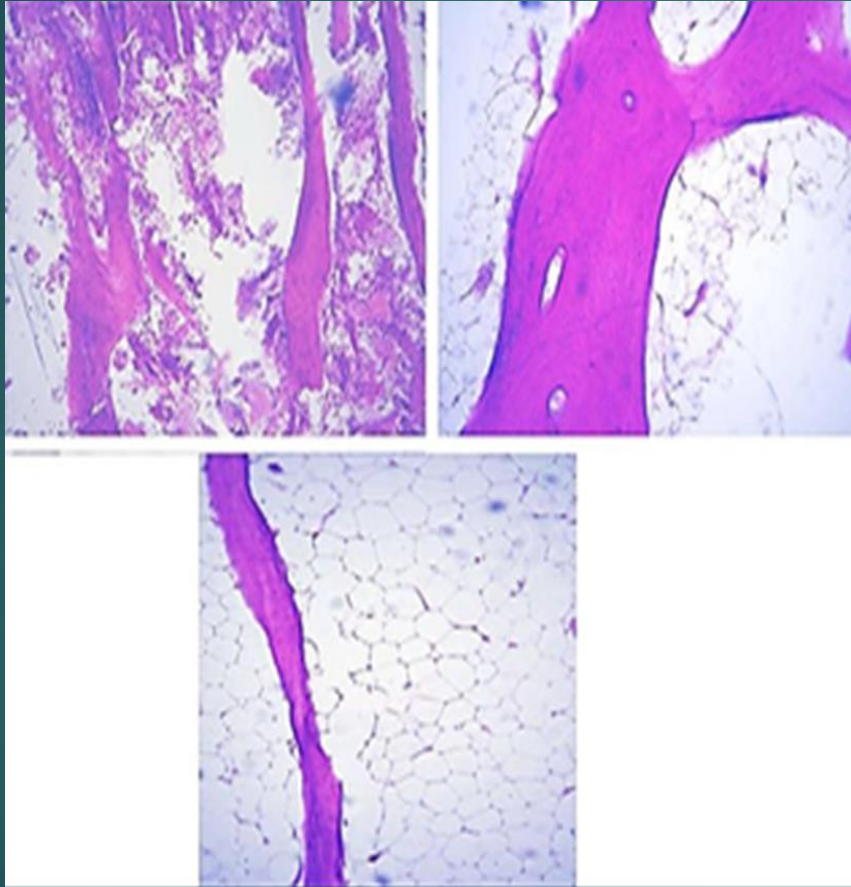
# Age morphology of thyroid cartilage



- ▶ We found the parameters which have a strong correlation with age and the level of diagnostic significance of each feature in different periods of life has been established.



# Micro-osteometric method of age determination

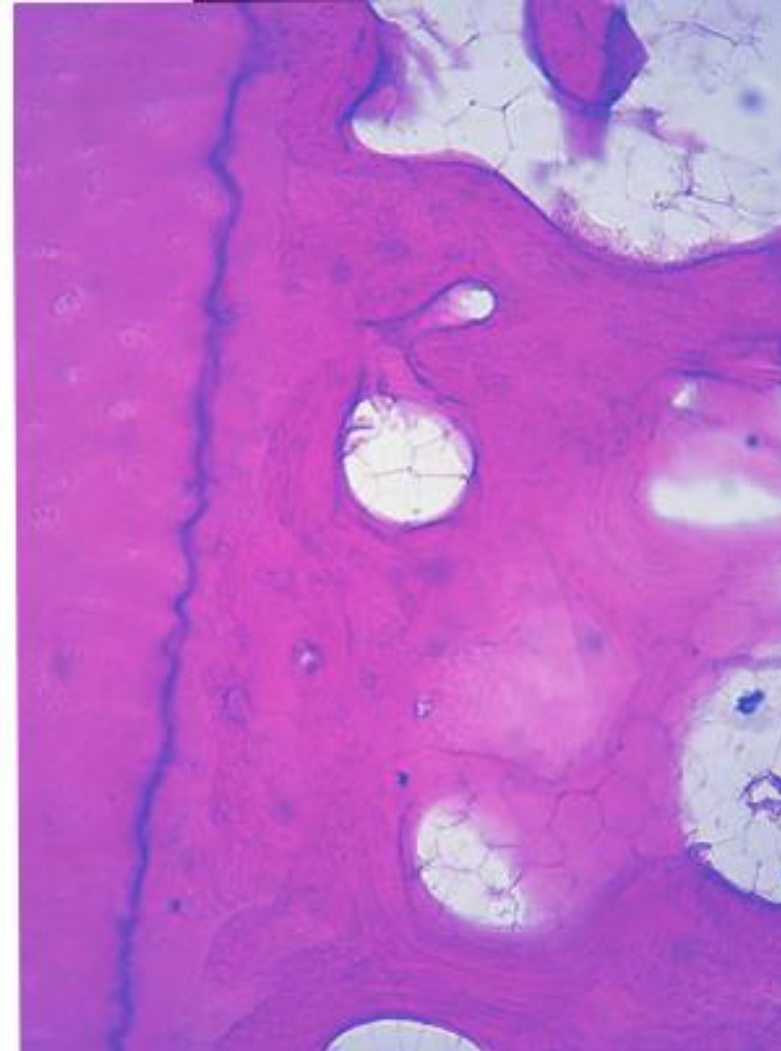
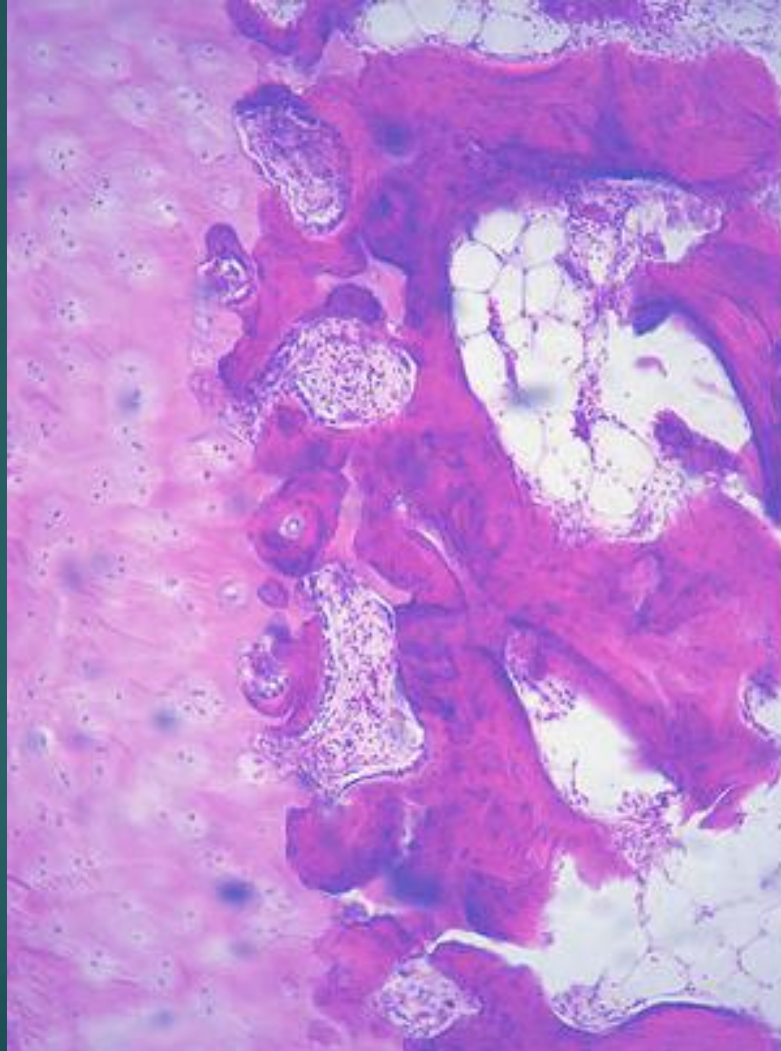


- ▶ Computer technologies for determining of the biological age of the individual (accuracy of establishing of the age is up to 3 years) have been created using the parameters of histological sections of the bone tissue of the rib and tibia

The line of mineralization of the articular cartilage of the lower epiphysis of the tibia:

12 years

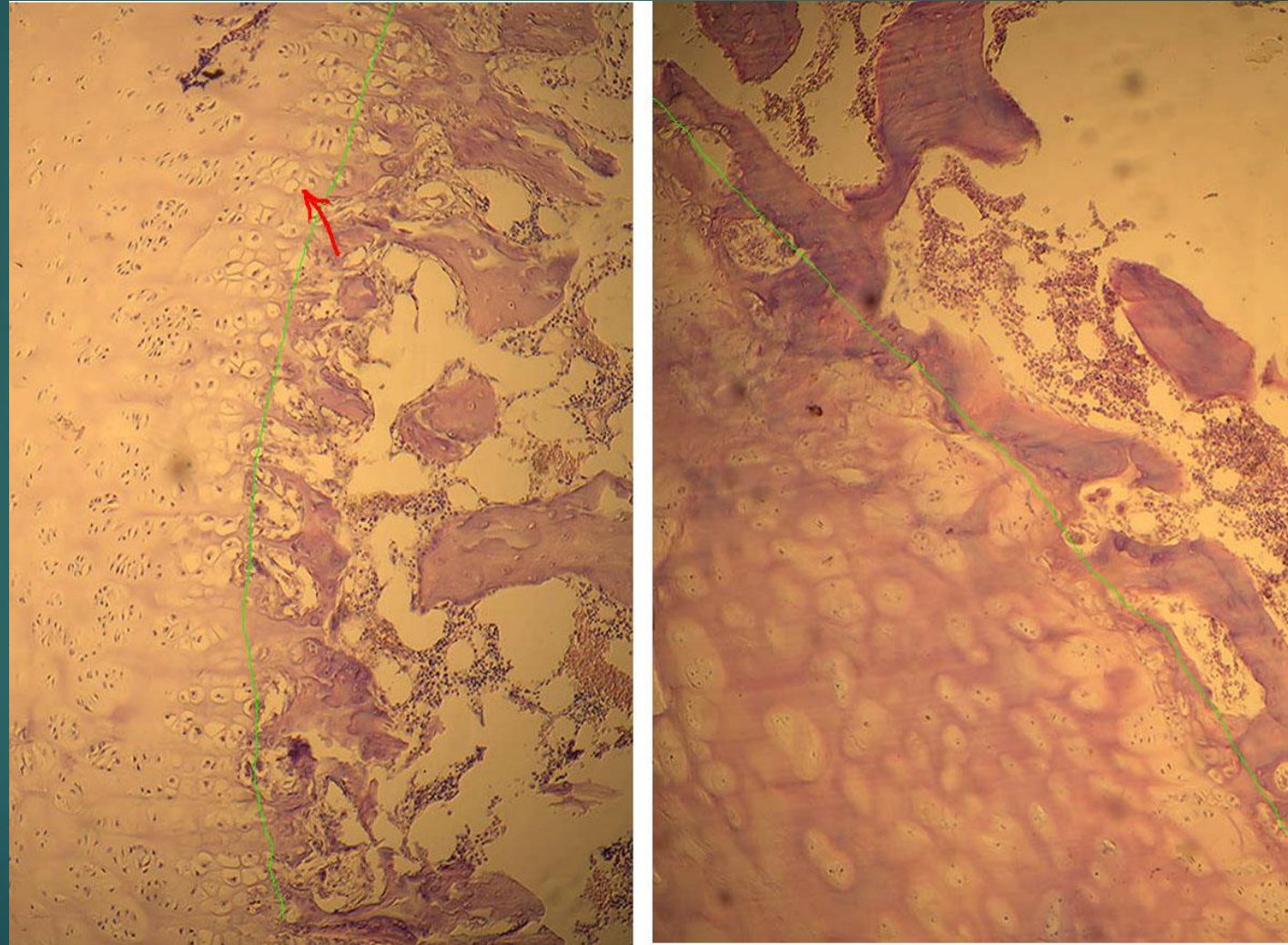
24 years old





The costal cartilage of a young man (18 years) and a man (35 years), the border of the bone tissue

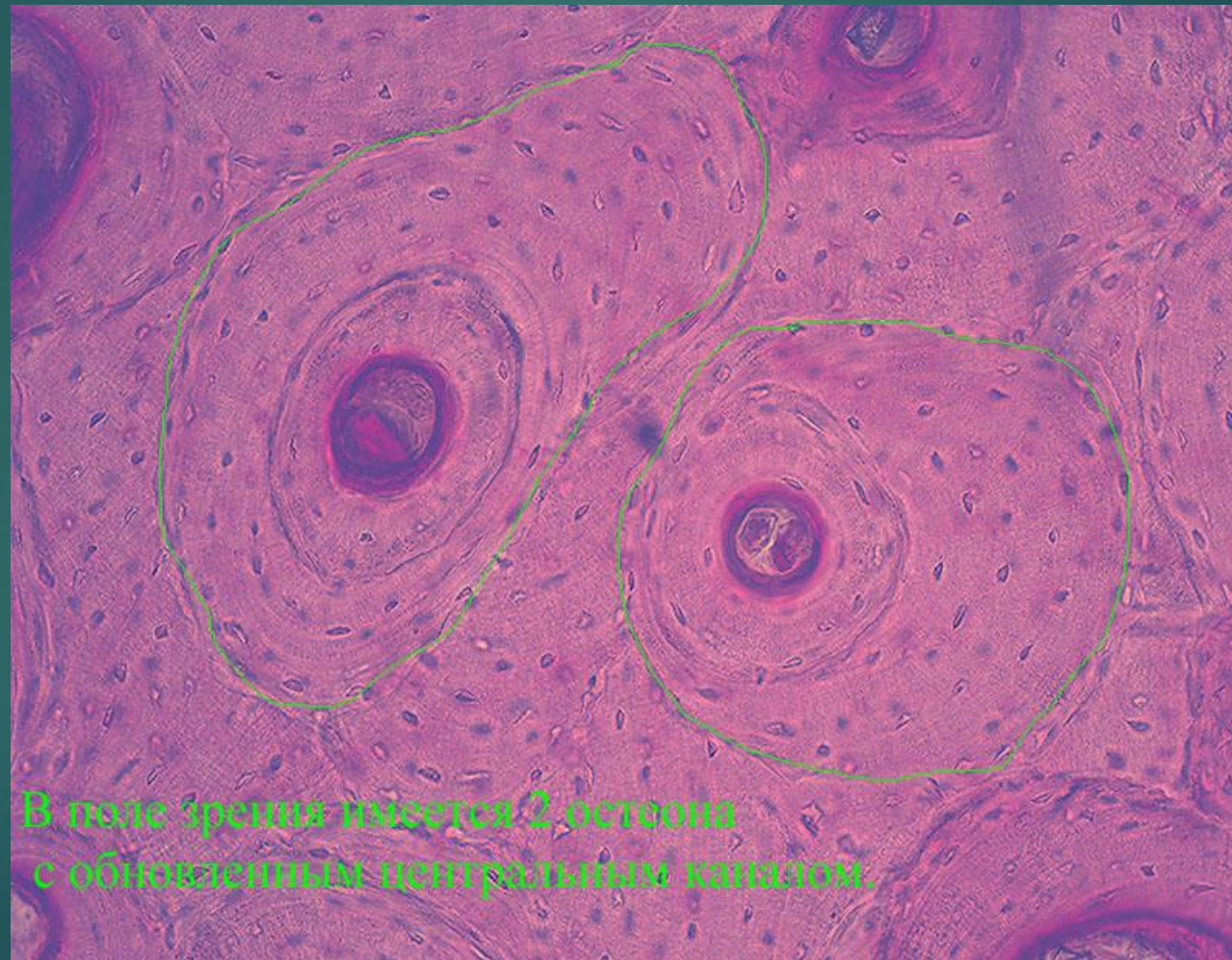
47



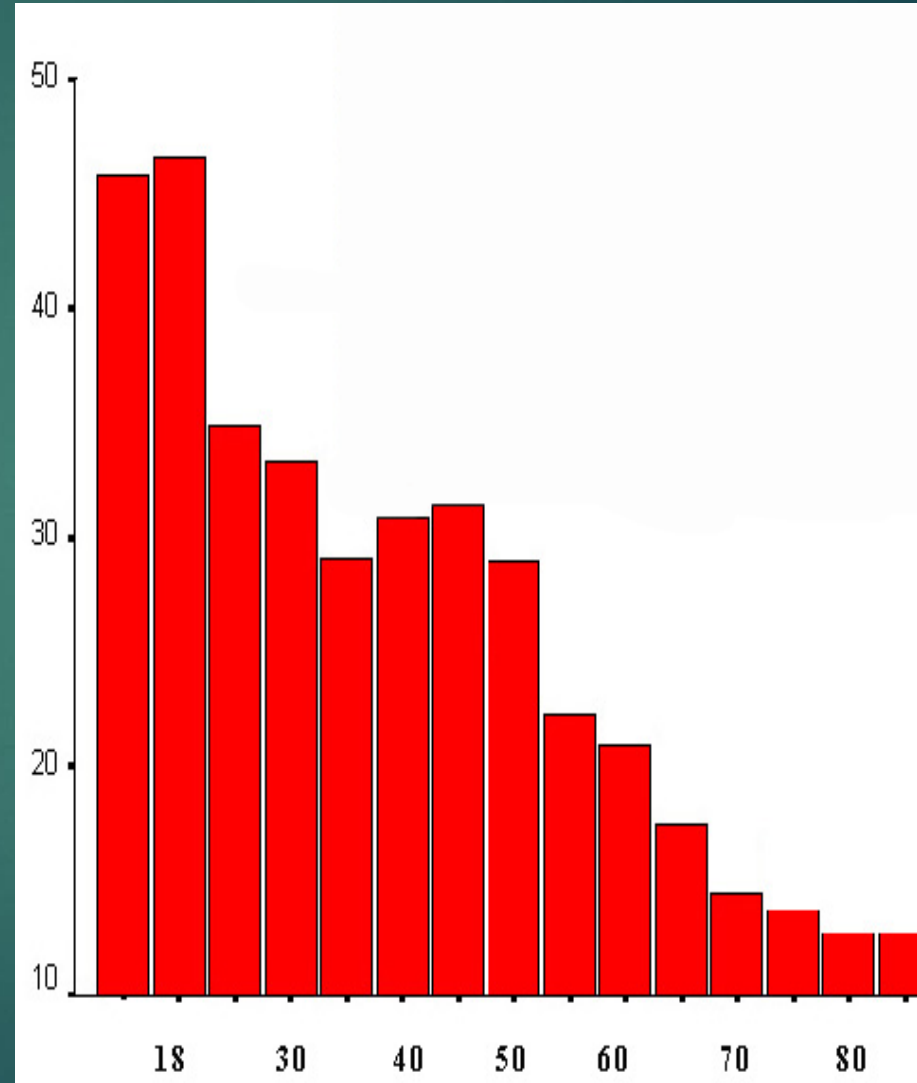
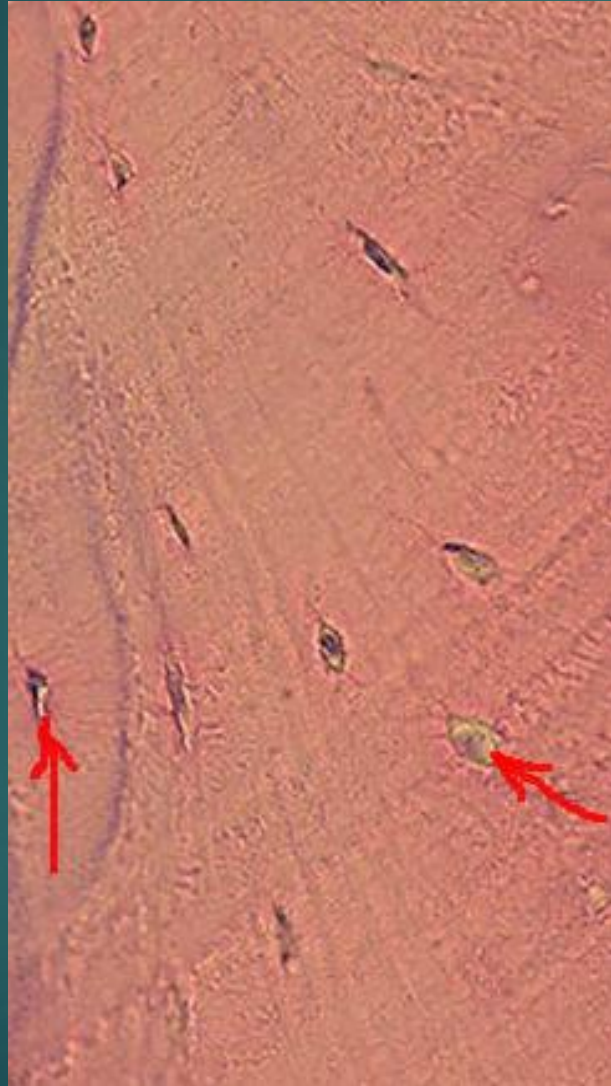


## Osteons with a reconstructed central part in a compact bone material of the tibial diaphysis

48



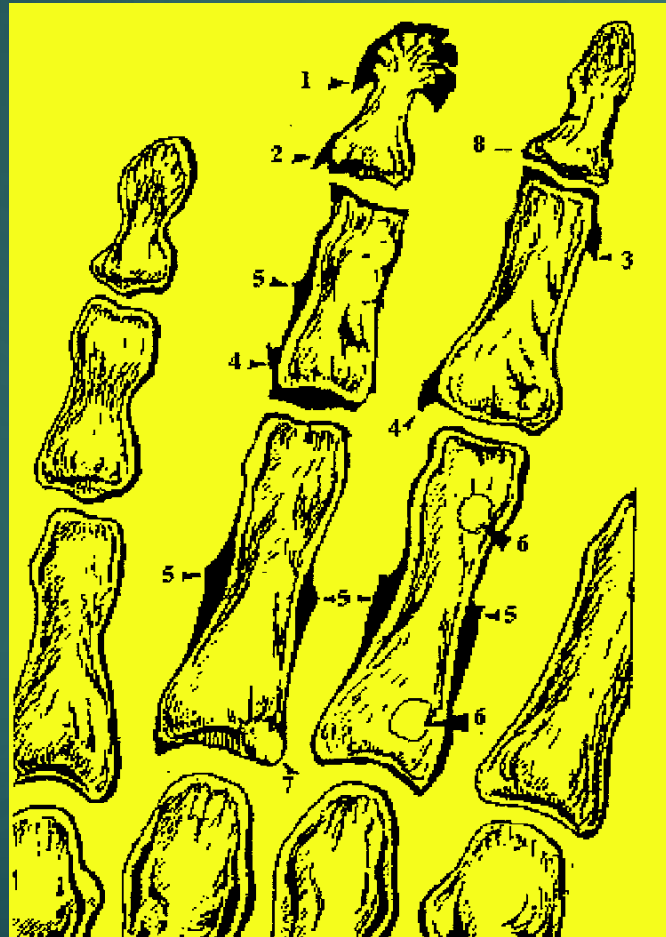
# Osteocytes in the cortical layer of the rib



# The method of age determination using the chest radiographs

## radiographs

The main signs of age-related changes in the bones of the hand



### Остеофиты:

1. Апофизоз
- 2, 3, 4 – различные узлы, разрастания на суставной поверхности фаланг.
5. Экзостозы на диафизах фаланг

### Порочические изменения костной ткани:

- 6 – Остеопороз
- 7 – Очаг атрофии








### Суставные деформации:

- 8 – сужение суставной щели.



# Age-related changes in the skeleton of the palm

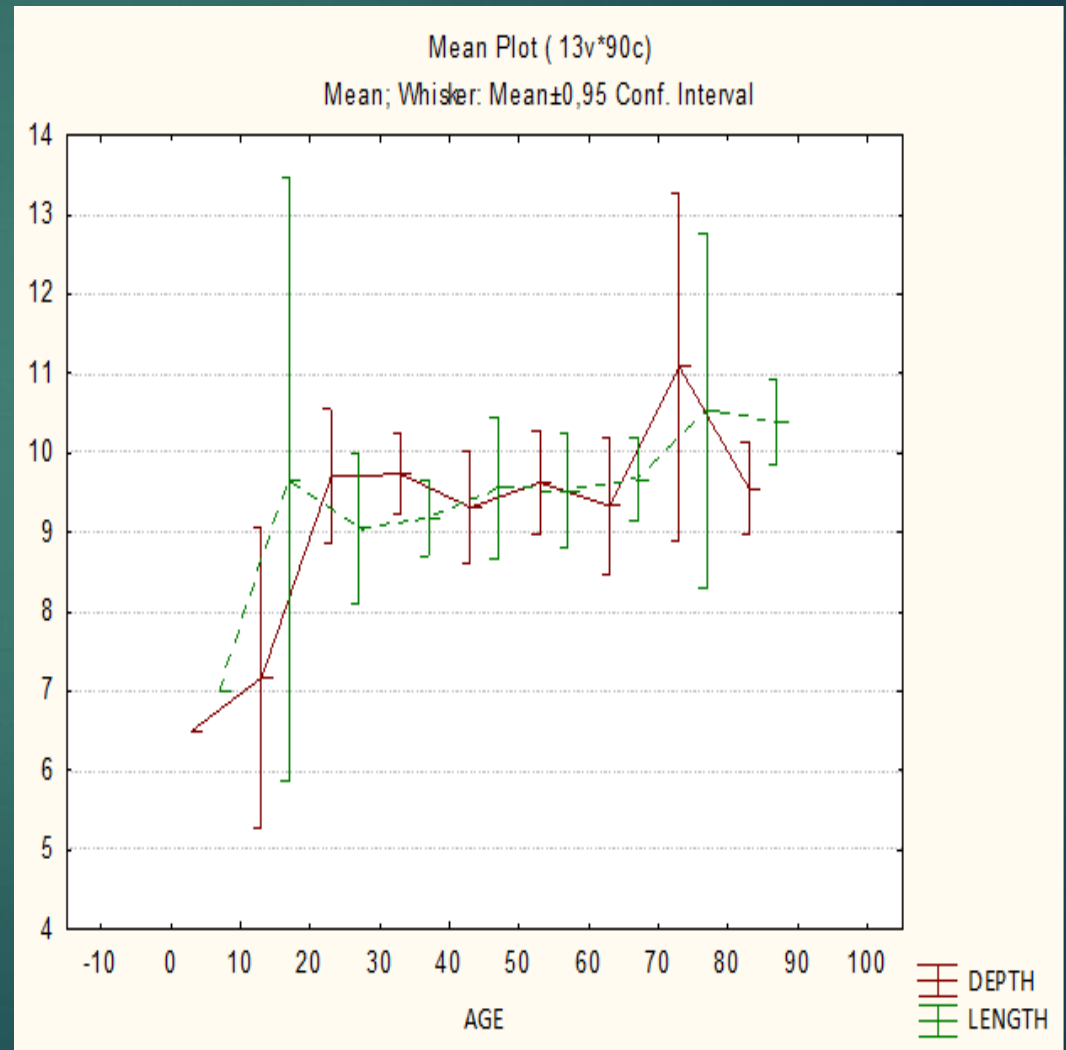
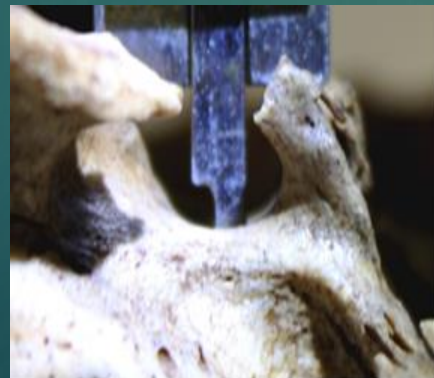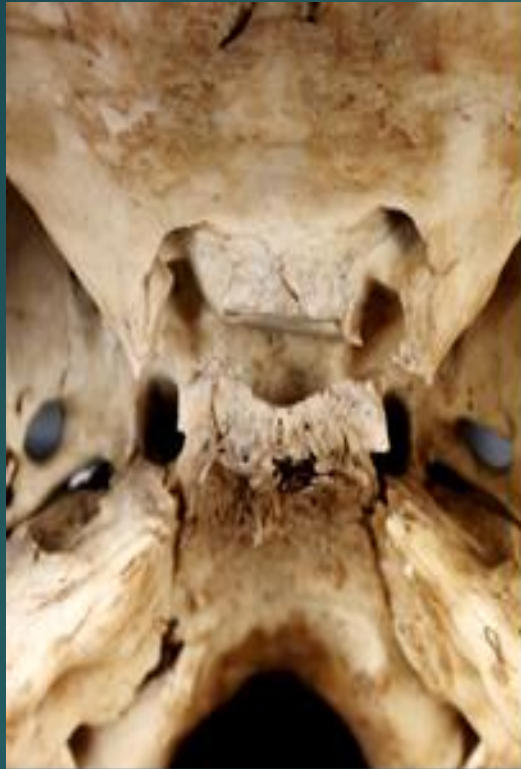51

25 – 30 лет	30 – 40 лет	40 – 50 лет	Более 50 лет
 <p>Апностоз</p>	 <p>Сужение суставной щели средних фаланг</p>	 <p>Узлы на суставных площадках</p>	Наличие практически всех признаков
 <p>Сужение суставной щели дистальных фаланг</p>	 <p>Разрастание на диафизах</p>	 <p>Увеличение числа разрастаний на диафизах</p>	 <p>Поротические изменения</p>

# Age morphology of the Turkish saddle

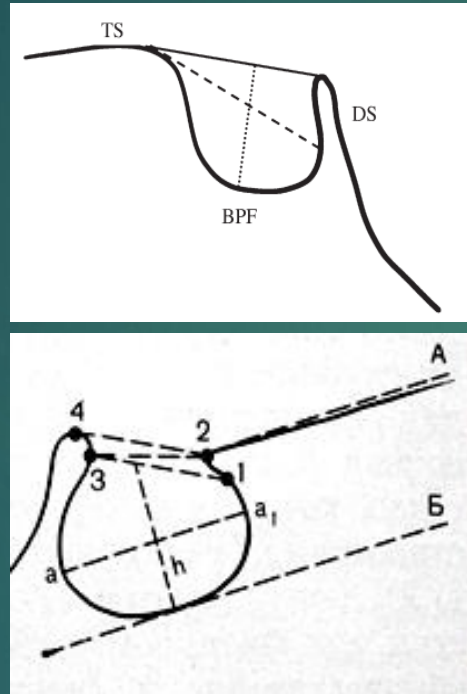
## Length, depth and top depth

52

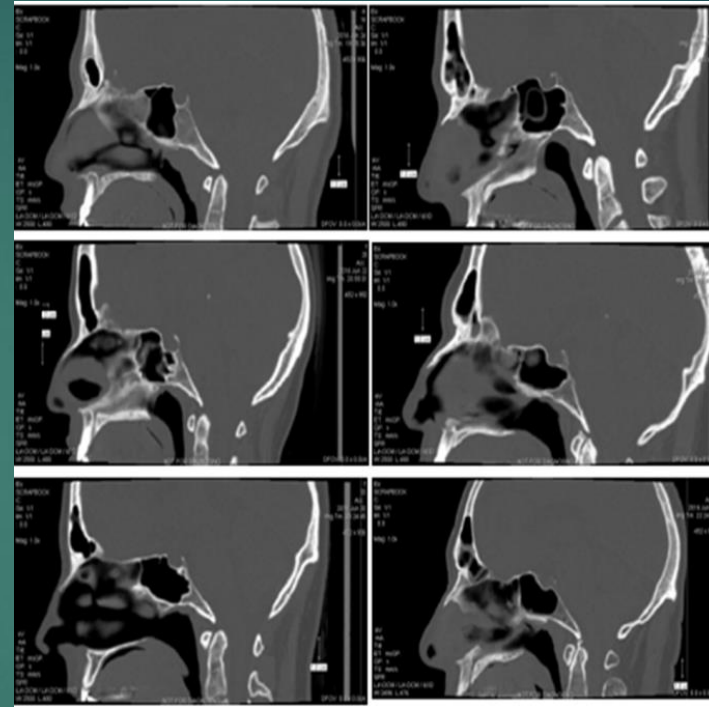


# Age morphology of the Turkish saddle

Osteometric examination



X-ray examination



The changes of sizes during life were determined,  
They were divided into the following age periods: the mature age of period I, period II; Elderly or senile age



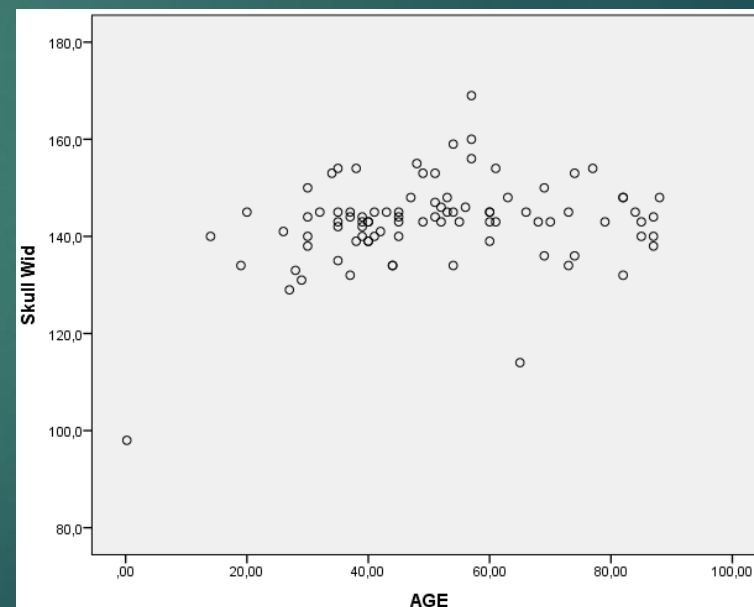
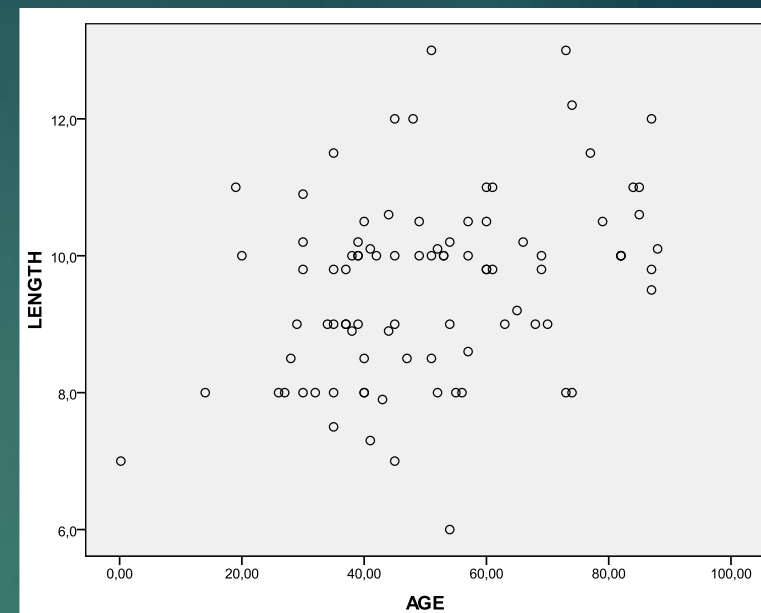
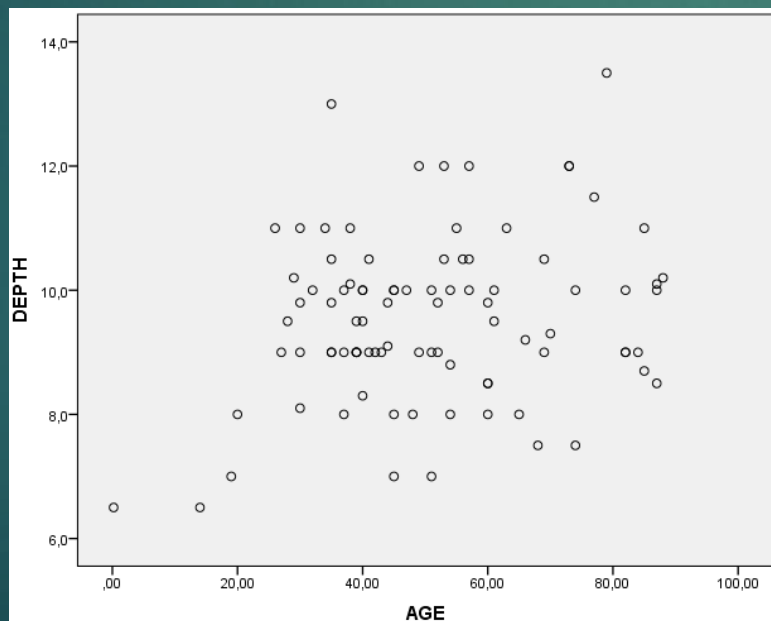
## Turkish saddle

Determination of metric parameters:

Age and depth of the Turkish saddle;

Age and length of the Turkish saddle;

Age and width of the skull



## Table of the regression model of the age forecast made by the morphometry of the Turkish saddle

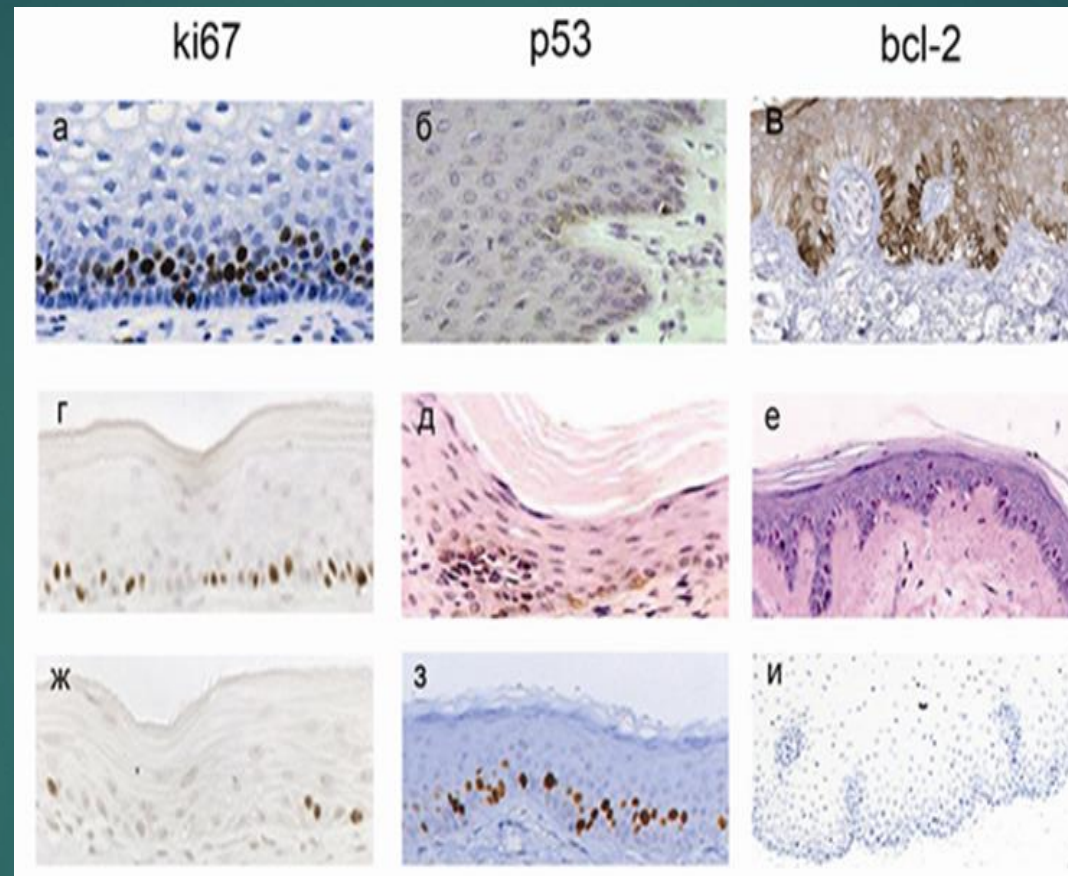
	Нестандартизованные коэффициенты		Стандартизованные коэффициенты
	B	Стандартная Ошибка	Бета
(Константа)	-18,6	17,712	
LENGTH	4,648	1,403	0,328
DEPTH	2,635	1,388	0,188

In accordance with the table, the expected value of age is calculated as:

$$\text{Forecast} = -18.6 + 4,648 \times \text{LENGTH} + 2,635 \times \text{DEPTH}$$

## ESTIMATION OF THE BIOLOGICAL AGE OF SKIN.

56



**Immunohistochemical markers Ki67, bcl-2, p53 were used as quantitative parameters of a complex evaluation of the biological age of human**



# Molecular autopsy

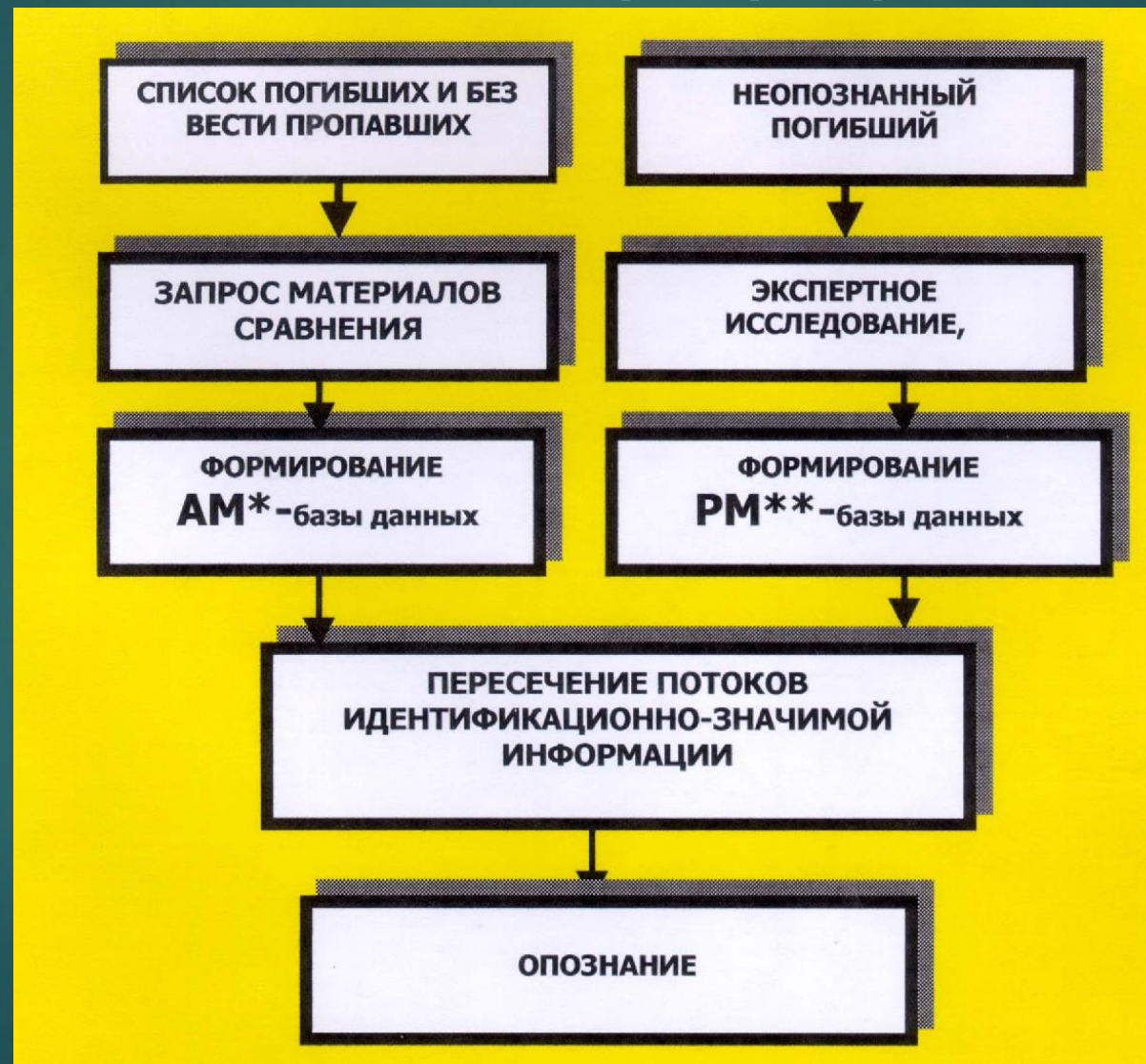57



- ▶ The possibility of usage of the signs of genetic predisposition to various diseases can be used in forensic identification.

# Algorithm of forensic identification of the person in cases of mass mortality of people

58



## Innovative achievements

- ▶ A new scientific area was created: the establishment of the biological age of a person using methods of quantitative age morphology
- ▶ The signs with the most pronounced dependence on age were established, their quantitative characteristics are determined, their age dynamics are described
- ▶ A new theory of age diagnosis has been formulated, taking into account the morphometric parameters of the vascular, nervous and bone tissues
- ▶ With the help of molecular autopsy, identifying signs of a person's genetic predisposition to various diseases have been developed



# Problems of forensic identification of a person

60

- ▶ Safety of biological material;
- ▶ The absence of a single bank of identification data makes it difficult to compare information on missing persons and unidentified corpses in Russia ;
- ▶ Comparison of large amounts of information in cases of mass mortality ;
- ▶ Absence of strictly individual biological signs.

To ensure the effectiveness of personal identification:

- ▶ Foundation of interdepartmental bank for the identification of unidentified corpses;
- ▶ Development of effective methods of personal identification based on uniform methodological principles.
- ▶ Development of specialized software for the identification database of unidentified corpses.
- ▶ Organization of the unified training for identification work.

**Thank you for your attention**